



2811634467

No. 5842/H

140H



THE INSTITUTE  
OF  
OPHTHALMOLOGY  
LONDON

EX LIBRIS

OPHTHALMOLOGY HC 723 STREATFIELD





Digitized by the Internet Archive  
in 2014

<https://archive.org/details/b21641225>

*J. F. Streatfeild's  
own Copy.*

# OPHTHALMIC SURGERY.

*Reviewed in "Lancet", 26<sup>th</sup> Dec. 1842, p. 603,  
" Edinburgh Medical J. December, " p. 552.  
" Brit. For. Med. Chi. Review, Jan. 1843, pp. 140-2.*

BY

J. F. STREATFEILD.

[PRINTED FOR PRIVATE CIRCULATION.]

1810939

# OPHTHALMIC SURGERY.

EXTRACTED FROM ERICHSEN'S SURGERY.

SIXTH EDITION, 1872.

BY

J. F. STREATFEILD.

---

---

## CONTENTS.

	PAGE
GENERAL REMARKS : operations on the eye . . . . .	2
OPERATIONS ON THE EYELIDS : tumours : ptosis : tinea ciliaris : trichiasis : symblepharon : entropion : ectropion . . . . .	4
OPERATIONS ON THE TEAR-PASSAGES : slitting the punctum and canaliculus : probing the nasal duct . . . . .	9
SQUINT-OPERATIONS . . . . .	13
OPERATIONS ON THE EXTERIOR OF THE GLOBE : pterygium : removal of foreign bodies : tapping the cornea . . . . .	16
OPERATIONS ON THE IRIS : artificial pupil : incision : iridesis : excision : iri- dectomy (glaucoma) : prolapse of the iris : synechiæ, corelysis . . . . .	21
CATARACT : forms : general remarks : flap-extraction : traction : Von Græfe's extraction : needle-operation : suction : secondary operations . . . . .	29
EXTIRPATION OF THE EYEBALL : abscission : staphyloma . . . . .	46
THE OPHTHALMOSCOPE . . . . .	51

[PRINTED FOR PRIVATE CIRCULATION.]

## CHAPTER LVI.

### OPHTHALMIC SURGERY.

[This Chapter has been written and contributed by J. F. STREATFEILD, F.R.C.S., Surgeon to the Royal London Ophthalmic Hospital, Moorfields, and Ophthalmic Surgeon to University College Hospital.]

OPERATIONS on the eye are in many ways peculiar. They specially demand an accurate knowledge of the anatomy of the parts concerned, of their relative connection and position. In eye-operations, any small error in estimating the relationships of the delicate parts constituting the organ of vision is much more likely to be injurious than in operations on other parts of the body. Again, as the eyeball is enclosed in dense firm membranes, capable of little or no extension, inflammation is fraught with very much danger to the future integrity of the parts. An external opening made into the globe in all probability soon heals; but the parts within, if there be inflammation, are perhaps in so much the greater danger; and, as the circumference of the globe is limited, the inflammation is so much the more and more continually aggravated. The re-absorption of inflammatory effusion, and the return to the healthy state, are hindered by the unaccommodating nature of the sclerotic and cornea. The optic nerve will give way, after some time has elapsed, in any case of intraocular pressure, with, of course, serious injury to vision (see Glaucoma, p. 358). The sclerotic or cornea may allow extension; and a corneal or sclerotic staphyloma, when these structures have been weakened and deteriorated, is formed, but very slowly, and the bulging is a permanent deformity almost always very seriously interfering with good vision. Inflammation of the eye, as of other parts—such as the testis—which are enclosed in inextensible fibrous coverings, is attended with pain in proportion to the unyielding nature of the envelope; but the functions of the eye are more readily destroyed, and we cannot in the same way relieve tension by strapping or by simple incision, nor can we so well apply cold externally. If one eye be destroyed by internal inflammation, especially of a traumatic nature, whether accidental or surgical, the other will not improbably follow it and also become blind by a peculiar “sympathetic inflammation,” to which the eye, among duplicate organs, is specially liable. In some cases this is almost certain; so that the Surgeon has then further a clear duty to perform. Inflammatory effusion or suppuration within other organs, is followed generally by much less destructive results as regards the integrity of the whole; in them, abscess probably soon finds a harmless outlet. A few ophthalmic operations, especially on the parts around the eye, resemble operations in similar cases in ordinary surgery, and are done according to general rules given in other chapters (see Chapter LVIII.).

It used to be always remarked of the diseases of the eye that, even of many of the internal changes, iritic, cataractous, &c., it was no small advantage that we could *see* their progress, and that their study was instructive inasmuch as it was the more certain. With the ophthalmoscope our advantages are tenfold increased, and we may *see* morbid processes existing even in the choroid or sclerotic coats, in the retina and optic nerve. Anæsthesia is an almost obsolete term, or is, as before, at any rate restricted to those (now com-



paratively few) cases of blindness in which we cannot see any morbid change—to nerve- or brain-diseases more or less affecting vision, and of which, even with the ophthalmoscope, we can find no evidence. But the ophthalmoscope has not added much to our powers of *surgical* treatment of eye-diseases. With its aid, detached retina has been evacuated and foreign bodies or cysticercus removed from the vitreous chamber. With it, also, we can often make a previous examination to find if there be any *deep-seated* disease to mar the good result otherwise to be expected of operation. If we include in the term ophthalmoscopic examination the lateral focal illumination of an eye by a convex lens and artificial light, our prognosis is of course by this often very much assisted in any proposed surgical interference, as it is in the diagnosis of many of the diseases, but only of those whose progress could be less perfectly seen and watched years ago, before the ophthalmoscope was invented and the lens used in this way,—the iritic, cataractous, and other cases of disease, not very deep-seated, above mentioned. This concentrated side light, or oblique illumination, has been used in some operations within the eye, such as those for the removal of foreign bodies in the iris or anterior chamber, at the time of the operation, as well as for the diagnosis and prognosis generally of these and other cases.

PERFORMANCE OF OPERATIONS ON THE EYE.—Nothing by way of gaining experience in eye-operations is of much account, except actually operating on the patients themselves. Short of this, it is most valuable to watch carefully the operations of others. In eye-surgery, practising operations on the dead subject is of little or no good to the beginner. When, in general surgery, a limb is to be removed, it is amputated at a distance from the seat of the disease; or, if an artery is to be tied, it is secured at a place remote from the aneurism, so that such operations may well be practised on the dead subject. But, in eye-surgery, we can never operate at a distance from the disease; either we are immediately concerned in the part that is diseased or we are close upon it, as in removing an opaque lens, or in performing iridectomy on an adherent iris. Squint operations (tenotomy), extirpation of the eyeball, tapping the cornea, slitting the canaliculus, and some of the first steps of the more important eye-operations, such as the making a section of the cornea, may be practised on the dead subject; but, as to all the rest, it is mere waste of time.

Almost all operations on the eye are done with the patient lying on a hard couch, not quite so high as an ordinary surgical operating table, with a hard pillow to raise the head of the patient a little, and comfortably. The foot of the couch is in a window, facing the north if possible, and giving a good light. The Surgeon stands behind the head of the patient, so as to use both hands conveniently, and to be out of the way of the light. A towel spread on the pillow is thrown from behind forwards over the patient's head, as far as his forehead, and this, at the temples, may be held, if necessary, on each side, by the hands of an assistant. In some cases the wrists of the Surgeon may be brought, on each side, up against the temples, to steady the patient's head when he is passive under chloroform. In eye-surgery, the arms are seldom required to be moved whilst actually operating. In these minute operations often the fingers only, seldom more than the hands as well, are necessarily changed from their first position. Perhaps some pronation and supination of the fore-arms may be called for; but, the patient being under the influence of chloroform, his head even then may be steadied or rotated or moved from side to side, as may be best, by resting the wrists against the temples of the patient. Even the ordinary internal squint-operation may be done from behind the head of the patient; but, in this case, the Surgeon is in

a better position when he is sitting on the edge of the couch, on the side opposite to that of the eye about to be operated on, so that he may be as little as possible in his own light. In either position, whether from behind or on one side facing the patient, he will, for one or the other eye, if both should require to be operated on, have to cross his hands, if not so ambidextrous that he can use the scissors with his left hand. And, in this particular operation, that the Surgeon is in an unfavourable position as regards light is of little importance to him. In using the spring-wire stop speculum to keep open the lids, it is a point worth remembering that, chloroform not being used, less pain will have to be borne by the patient, if, when the speculum has been allowed to open to the widest extent, it be then a very little closed and then so much fixed open. In many very trifling operations a speculum is often used, when chloroform is quite unnecessary, and when the instrument would not be wanted at all by a practised operator, who prefers his fingers. The same remark often applies to the use of forceps, for fixing the eye (see Tapping the Cornea, p. 352). It is well if the fingers can be made to answer the purposes of speculum and forceps; but such pressure on the globe of the eye with the fingers as is required, when they are employed not only to keep the eye open, but to fix the globe, would be dangerous in any case in which any considerable opening is to be made in the coats of the eye, as in some of the cataract operations, iridectomy, &c. Operations on the eyelids and conjunctiva, the skin, and mucous membrane, are probably very much more painful than are any of the internal operations on the eye: therefore an anæsthetic may be used in such cases for the sake of the patient. In the major (internal) operations on the eye we must use the anæsthetic very much for the advantage of the operator; to whom any little movements of the patient, during an operation, are a great inconvenience, if they be not actually dangerous to the result.

In testing the amount of vision of a cataractous or otherwise blind eye (so called) we must cover the other. So also, to produce perfect seclusion of an eye, whether after operation or not, we must cover both; because the two eyes, their irides, and the muscles of the globe, act together. And whenever a shade is ordered, it should be over both eyes. Of eye-bandages, the best, unless much pressure be required, is Liebreich's, which consists of an oblong piece of knitted cotton with a piece of tape sewn to it at one end, and at the other two such tapes, which are joined, and have beyond them another single tape. The two tapes are put one above and the other below the occiput to steady the bandage, and the two single ends of tape are tied together, as tightly as may be required, round the head. If common bandages be employed, the two ends may be tied in a knot on the side of the head opposite to that of the eye affected; or, the two ends being split for a short distance, the two lower half ends may be tied above the occipital protuberance and the two upper ones below it. The object is to employ no more length of bandage than may be required, and to prevent the bandage from becoming shifted. A narrow flannel bandage, long enough to be passed many times round the head, is the best bandage when pressure on an eye is required.

#### OPERATIONS ON THE EYELIDS.

We are here only concerned in those operations which are, at least to some extent, peculiar to the eyelids.

**TUMOURS.**—Of tumours there are here, as elsewhere, many kinds.

*Molluscum* is <sup>as has been said</sup> very common about the skin of the eyelids. This is best treated by thrusting a sharp-pointed knife through the tumour, with the back of the

... surgical method is of any avail, in the conjunctival sac, & that the operation may be always of a successful nature.

... of the levator palpebrae muscle has sometimes been done in a complete manner for the advancement of the eye, & has been brought forward, & has been repeated the operation and removed a piece of skin in one or two cases.

**TRICHIASIS.**

knife towards the base, and cutting outwards so as to divide the upper half of the growth. Then with the ends of the two thumb-nails, one on each side, pressed together below the base of the tumour, the whole is turned out easily at once.

A Sebaceous Tumour, often containing hairs, is of frequent occurrence, especially at the upper and outer margin of the orbit. It should be dissected out altogether. It is generally very difficult or impossible to remove the whole without opening or bursting the sac.

The common Tarsal Tumour, as it is called, probably has its origin in disease of the Meibomian glands. If left some months, it may become as large as half a pea; and then it suppurates, and at last bursts on the conjunctival side of the lid. It should be opened, as soon as, when the inner surface of the lid is exposed, the situation of the tumour is shown by a greyish semi-transparent spot. Of course, if it have suppurated, it should be opened. By two punctures a crucial incision is made in the more transparent part of the tumour, and the whole soft contents are squeezed out with two fingers. The contents are probably firm, and cannot be evacuated, if the semi-transparent spot do not appear.

PROSIS.—The muscle that should raise the upper lid is sometimes permanently paralysed, and then it may be noticed that the occipito-frontalis muscle of the same side, in endeavouring to raise the lid, has corrugated the skin of the brow, on the side of the paralysed muscle. Hence, in order to make more use of this new action of the occipito-frontalis, an operation is sometimes employed when all else has failed.

It consists in the removal of a horizontally oval piece of skin and some subcutaneous parts of the upper part of the upper lid, of a sufficient size to allow the upper lid to cover the globe, and yet, when the patient lifts his brows, that the cornea may be readily uncovered. A fold of the skin is seized with forceps at the place from which it is to be taken; and if it seem to raise the lid enough, and not too much, it is cut away with scissors to just that extent, and an oval wound is left. The loose and vascular skin of the lids will very soon heal without the application of surface.

TINEA CILIARIS is very common, but only among the very poor. Great cleanliness is required. The eyelashes should be kept cut as short as possible, for the better application of any ointment or lotion that may be prescribed, and for the more effectual removal by bathing of any accumulations of discharge from the edges of the lids. In chronic cases these dried accumulations should be at once removed by bathing and wiping, or with forceps, and, the lashes being cut close with scissors, the excoriated parts beneath lightly touched, at intervals of a week, with the solid nitrate of silver. The edges of the lids should be kept greasy always, meanwhile, with the citrine or some other ointment.

TRICHIASIS.—Trichiasis is an ingrowing of some of the lashes, as distinguished from Entropion, which is an inturning of the whole lid. In both, the lashes are in contact with the globe of the eye; but in entropion the lid may be temporarily rectified and held in proper position, and the lashes are not then turned in; whereas in trichiasis the eye cannot be freed from the lashes that are in contact with it without the lid being drawn away, apart from the globe of the eye, as it is abnormally in Entropion.

Causes.—Of the causes of trichiasis the commonest is, perhaps, the treatment of "granular" lids by solid caustics applied too exclusively to the lining membrane of the lid just within the margin, whereas any local applications of the kind should be, at least equally, applied far back. (In these cases entropion and trichiasis are often combined—see "Entropion.") Vascular nebula and pannus may then very probably result from the irritation; first, of

the granular conjunctiva, and, secondly, of the superinduced trichiasis. It is, perhaps, because granular conjunctiva chiefly affects the upper lid, that trichiasis most often occurs in it, and so, of course, pannus appears first at the upper part of the cornea. As to the so-called *Distichiasis*, the disease has no real existence; there are no cases in which two rows of lashes exist separately.

Cases of trichiasis vary so much, and the modes of operating are necessarily so various, that only a few of the operations can be here detailed, and a few practical facts noted. The practice of pulling out the ingrowing eyelashes is worse than useless; because they only grow again, the hair-bulbs being left. The case is therefore only temporarily relieved, and, in the end, vascular nebula of the cornea and consequent blindness are produced by the constant mechanical irritation of the inverted eyelashes. Lashes should only be pulled out as a temporary expedient. Patients sometimes come to the hospitals, almost blind, who have been taught by Surgeons to practise the pulling out of their ingrowing lashes; they have done it for years, they have their own tweezers and looking-glass for the purpose, they are relieved each time *temporarily*, but, far from being cured, are always by little and little becoming worse. Again, they not unfrequently break off the lash, and then the broken end causes more irritation and pain than the whole lash had done before. An eyelash, when it is to be pulled out, should be properly seized, near the skin, with broad and rough-ended forceps, and very steadily drawn in the direction in which it grows. But a patient will twitch it out quickly with his tweezers at right angles to the direction of the growth of the lash, and so it is very liable to be broken off.

If only one or two lashes grow in they may be pulled out, once or twice, in the hope they will not grow again nor again be so misdirected. But if many lashes grow in, or if a few only be always growing in, they must either be excised with their hair-bulbs, or an attempt must be made, by producing cicatrisation, to give a right direction to their future growth. The latter operation, being more tedious and less certain in its results, is not worth performing, except on young persons or those to whom personal appearance is important. When the hair and hair-bulbs are extirpated, the whole row of lashes of each lid operated on should generally be removed, though some only here and there be inverted, unless those which are turned in be all at one part of the margin of the lid. In such a case, a small round piece of the skin and all the structures down to the cartilage may be excised, *close to the edge of the lid*, so as to expose the roots of the inverted lashes, and the lashes drawn outwards with many fine sutures, inserted wherever they seem to be most required; after which the scar may effectually evert the ingrown lashes. If the whole row of lashes, or, perhaps, even if some all along the edge of the lid, be growing in, a similar operation to that last described, but extending the whole length of the margin of the lid, may be done. If this should fail, the lashes may afterwards be wholly extirpated. The excision of a part of the row of hair-bulbs is very often unsatisfactory, because the subsequent cicatrisation at the extremities of the wound will often draw in and invert some of the nearest lashes of those rightly directed.

*Excision of Hair-bulbs* is thus done. A forceps (*compressorium*), having for its lower blade a slightly curved plate of metal, has this blade placed under the lid, between it and the globe. The other blade, the skin of the lid being drawn away from its margin, is then brought down upon the outer surface, and is screwed down, so as to steady the eyelid between the two blades and hold it just firmly enough to control the bleeding, which in any operation

on the eyelids is liable to be considerable and troublesome. This upper blade, to admit of operating, unlike the lower one, is but a skeleton, leaving all the centre of the lid and its margin, on the outer side, exposed (Fig. 451). With a scalpel, two incisions are made along the margin of the lid, one on each side of the row of eyelashes, carefully including all of them; the knife, for both incisions, being held in the direction of the growth of the lashes and made to cut deeply. The ends of the incision are curved into each other, and then the piece of skin, &c., including the lashes, is detached altogether with scalpel and forceps. The inner of the two horizontal incisions is the important one. It must be made, with a firm hand, within every ingrowing eyelash, but in a regular curve, so as not to make an irregular edge to the lid. This incision often carries away with it a longitudinal strip of the cartilage, which gives shape to the lid. It should not trench on the conjunctiva or on that aspect of the lid. Then, if any of the bulbs have been cut through and are left, they should be removed: they are easily seen in the wound as little dark points. No sutures are necessary; the skin of the lid is abundant.

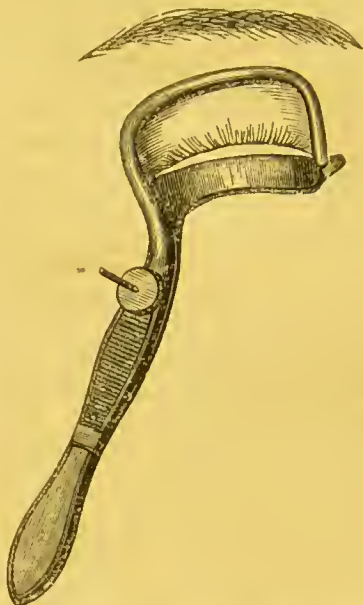

Fig. 451.—Forceps applied for Excision of Hair-bulbs.

When the palpebral and ocular conjunctivæ, or the margins of the lids have become united, <sup>burn or other</sup> ~~the~~ <sup>after an injury, there are cicatricial bands between</sup> ~~the~~ <sup>(Symblepharon)</sup> ~~edges~~ <sup>of these bands, they should be of course</sup> ~~divided, and,~~ <sup>to</sup> ~~to~~ <sup>hinder their reuniting, their cut surfaces may be touched with nitrate of silver,</sup> ~~occasionally.~~ <sup>oiled lint interposed, and a probe passed along the track of the wound, occa-</sup> ~~sionally.~~ <sup>But, unless a probe can be, in any such case, in the first instance</sup> ~~passed freely under the bands, so that they may be isolated, they will probably~~ <sup>reunite to such an extent, that the operation will have been almost useless.</sup> ~~A~~ <sup>better plan, perhaps, than dividing the band when the union is inconsiderable,</sup> ~~is to tie a strong ligature, passed beneath such a band, around it, and then let~~ <sup>it drop out in the course of time.</sup> ~~If a probe cannot be passed under and~~ <sup>around the adherent surfaces, or union of the edges of the lids, it may be first</sup> ~~of all advisable to pass a few silk threads, to be secured and left for some~~ <sup>weeks, so as to make a fistulous track which shall be the limit to which it is</sup> ~~intended to free the lid, when the parts united are afterwards cut through.~~

**ENTROPION.**—If, in a lax state of the lids, as when a patient has lately become thin, anything should <sup>excite</sup> the action of the orbicularis muscle, those fibres next the edge of the lid, <sup>often</sup> not unfrequently cause <sup>them</sup> to become rolled inwards; and then the irritation of the lashes against the ocular conjunctiva tends always to aggravate this state of the parts, set up, accidentally as it were, in the first instance, by some other irritation. This abnormal condition is most commonly seen in the lids of old people, and especially in the lower lid, which is kept out less than is the upper lid, by the convexity of the globe of the eye. For instance, it is a not infrequent occurrence, and must be looked out for, and at once remedied if it occur, after the operation for senile cataract.

The lids of old people contain but little fat, <sup>perhaps, a chronic conjunctival inflammation, in the case of senile</sup> ~~the~~ <sup>the</sup> ~~margin~~ <sup>of the lid</sup> ~~lies~~ <sup>is bathed in tears, and so the more</sup> ~~in many folds, and~~ <sup>very often, too,</sup> ~~after an operation, the~~ <sup>water-dressings</sup> ~~margin~~ <sup>is applied.</sup> ~~of the lid is~~ <sup>Some</sup> ~~bathed in tears, and so the more~~ <sup>often, too,</sup> ~~very often, too,~~ <sup>water-dressings</sup> ~~is applied.~~ <sup>Some</sup>

*Handwritten notes:*  
 (Symblepharon)  
 of these bands, they should be of course  
 to  
 hinder their reuniting, their cut surfaces may be touched with nitrate of silver,  
 oiled lint interposed, and a probe passed along the track of the wound, occa-  
 sionally.  
 But, unless a probe can be, in any such case, in the first instance  
 passed freely under the bands, so that they may be isolated, they will probably  
 reunite to such an extent, that the operation will have been almost useless.  
 A  
 better plan, perhaps, than dividing the band when the union is inconsiderable,  
 is to tie a strong ligature, passed beneath such a band, around it, and then let  
 it drop out in the course of time.  
 If a probe cannot be passed under and  
 around the adherent surfaces, or union of the edges of the lids, it may be first  
 of all advisable to pass a few silk threads, to be secured and left for some  
 weeks, so as to make a fistulous track which shall be the limit to which it is  
 intended to free the lid, when the parts united are afterwards cut through.  
 perhaps, a chronic conjunctival inflammation, in the case of senile  
 the margin of the lid is bathed in tears, and so the more  
 very often, too, water-dressings is applied. Some  
 Or it will bear  
 the good result, and  
 of course, in any case,  
 Entropion would be  
 readily rectified  
 or the Cornea will  
 suffer by the me-  
 chanical irritation  
 of the edge of the lid  
 the lashes, such as  
 follow from  
 eyelid trichiasis

is in very likely will be... The edge of the eyelid... turned over inwards... very little altered in appearance... probably, <sup>in the</sup> eyelid... more rounded, and the eyelashes are very abundant. This is especially true of the upper lid... It is probably a... make a... little but... devised for... for any... Any efficient... much as to imitate the action of a finger employed in... "muscular lid" (Trichiasis) in both... It is a... of the eye... **OPHTHALMIC SURGERY**... highly need... for this disease... fullness... and... of the... slight irritation or pain produces—voluntarily or involuntarily—an extra contraction of the orbicularis, and the edge of the lid is tilted inwards. Though the irritation of the lashes is, in these cases, very much less than might be expected, and is not at all comparable to that arising from trichiasis or entropion in younger persons, in whom the lashes are stiffer or grow irregularly, the orbicularis is stronger and the lid altogether firmer; it must be looked for and prevented. The patient should be taught, when the inversion occurs, to put his finger on the skin of the lid, and so pull it down and replace the inverted edge of the lower lid and the lashes. Water-dressings must be avoided. Very probably, however, this will not be sufficient; and then, the skin of the lower lid being drawn down and well dried, some collodion should be painted along the edge of the lid with a large brush, and the parts kept still until it is dried. If insufficient to remedy the abnormal condition, the following operation, applicable also to many cases otherwise originating, in which the skin of the lid is abundant, should be done: An oval piece of the skin of the lid, quite close to the margin, must be excised horizontally. As much as is sufficient of the skin and subcutaneous tissues is seized with toothed forceps, raised a little, and cut away with scissors curved on the flat. The lid is drawn open a little and steadied by the finger of an assistant, or by the little finger of the left hand of the operator, which holds also the forceps. Then all those fibres of the orbicularis nearest to the edge of the lid are snipped away with the scissors, so that the cartilage is quite exposed. No sutures are required, as a very speedy union of the edges of the wound is not desirable, because a broader, firmer cicatrix is obtained by a slower process of healing. Enough of the skin should be removed, and all the inner fibres of the muscle causing the inversion. By this skin resection, if not enough of the orbicularis is removed, more difficult, because more complicated cases, of older date and yet of common occurrence, are those in which the lid, its cartilage, and altogether thickened, generally as a result of the application of caustics in the solid form to the palpebral conjunctiva for a longer time than was needed, probably for granular lids, or which too near to the margin only of the lid. The upper lid is the one most frequently affected. This is the commonest cause of trichiasis; but it may result in entropion, or in both together. The trichiasis must be treated by excision of the hair-bulbs or otherwise, as may be required. The entropion may be remedied in these, and in such cases the thickening of the lid, by "grooving" the outer surface of the length of the cartilage, near its margin, by first exposing it, and then making two longitudinal vertical incisions into the cartilage two-thirds or more through its thickness, inclined to each other, so that they meet below and form a V-shaped groove along the edge of the lid. Then, if there be no wrong direction in the growth of any of the lashes (trichiasis), but only the regular row is carried in with the inverted lid against the eye, a few fine sutures are introduced through the skin of the edge of the wound, next the margin of the lid, and then through the edge of the groove in the cartilage, farthest from the lid's margin. If the lashes have been removed for concomitant trichiasis, the fine sutures are merely put through the two lips of the skin-wound, so as to approximate the sides of the groove in the cartilage, and keep out the incurved margin. In some cases of entropion, an operation, the reverse of that sometimes adopted in cases of ectropion, the V-Y-operation, may be done, a Y-shaped incision made through the skin and subcutaneous parts of the (lower) lid, and the point of the angle, being dissected up, extended down below the point from which it was taken, and then secured, with some fine sutures, so that the lower part of the wound is flattened.

It is of some few of the wrinkles are affected also by the disease, so that, when the eyelid is placed, it will be placed in its right position in relation to the globe, hence there are few wrongly directed inward, or will be able to introduce the sutures, as the skin margin, since wherever there are ingrowing (or wrongly directed) lashes, are found, of course the greatest effect of flattening the margin of the lid is so far as when the distance were actually introduced.

Of those in which the lid, its cartilage, and altogether thickened, generally as a result of the application of caustics in the solid form to the palpebral conjunctiva for a longer time than was needed, probably for granular lids, or which too near to the margin only of the lid. The upper lid is the one most frequently affected. This is the commonest cause of trichiasis; but it may result in entropion, or in both together. The trichiasis must be treated by excision of the hair-bulbs or otherwise, as may be required. The entropion may be remedied in these, and in such cases the thickening of the lid, by "grooving" the outer surface of the length of the cartilage, near its margin, by first exposing it, and then making two longitudinal vertical incisions into the cartilage two-thirds or more through its thickness, inclined to each other, so that they meet below and form a V-shaped groove along the edge of the lid. Then, if there be no wrong direction in the growth of any of the lashes (trichiasis), but only the regular row is carried in with the inverted lid against the eye, a few fine sutures are introduced through the skin of the edge of the wound, next the margin of the lid, and then through the edge of the groove in the cartilage, farthest from the lid's margin. If the lashes have been removed for concomitant trichiasis, the fine sutures are merely put through the two lips of the skin-wound, so as to approximate the sides of the groove in the cartilage, and keep out the incurved margin. In some cases of entropion, an operation, the reverse of that sometimes adopted in cases of ectropion, the V-Y-operation, may be done, a Y-shaped incision made through the skin and subcutaneous parts of the (lower) lid, and the point of the angle, being dissected up, extended down below the point from which it was taken, and then secured, with some fine sutures, so that the lower part of the wound is flattened.

It is of some few of the wrinkles are affected also by the disease, so that, when the eyelid is placed, it will be placed in its right position in relation to the globe, hence there are few wrongly directed inward, or will be able to introduce the sutures, as the skin margin, since wherever there are ingrowing (or wrongly directed) lashes, are found, of course the greatest effect of flattening the margin of the lid is so far as when the distance were actually introduced.

When it does occur in the elderly or old persons, of whom it has been speaking, is generally found in the lower lid, in children, who are probably suffering from the intolerance of light, and excessive action account, possibly by external or internal causes. The former, causes lidemia, or eversion of the orbicularis, to keep the eyelids shut, and the latter, gradually the silver, by protecting the skin; in these cases the eversion of the eyelid is not so much a disease, as another cause to them, which had better be kept up, the eversion. With children, however, all inward SLITTING THE PUNCTUM is not a disease, but in these cases, treatment, general, including the cold douche, will probably suffice, and as the orbicularis, etc. subsides, the eversion, by slipping, will disappear.

ECTROPION. For this morbid condition, and, in a less degree, for entropion, it is not possible to point out any single operation as a cure. Neither of them is a disease, but the result of various diseases; and even though two cases of entropion, for instance, may be considered due to the same disease, they will very probably call for different methods of treatment. Some operations in these cases are often, however, applicable in a general way, as the disease which has been their origin is common to them. In thin old people, who have been stout, a weak orbicularis muscle, with loose skin, induces passively, on any slight provocation, entropion of the lower lid, and perhaps also consequently lacrymation (which always aggravates the eversion of the lid—see "Slitting the Punctum," below). The very existence also of the entropion in time only aggravates the disease by exposure, and consequent thickening, of the conjunctiva. A tendency to entropion or ectropion may often be remedied by means which in a normal lid would produce the contrary results. Thus caustics too freely applied to the conjunctival surface of the margin of the lid, it has been said, have often caused entropion. So, also, if sufficiently used, the application of nitrate of silver, or some other caustic, from time to time, will sometimes cure a slight entropion. It has been said that a weak orbicularis induces a passive entropion; and also that a removal of some too powerful and active fibres of the same muscle, next the lid's margin, will cure many trifling cases of entropion. Severe cases of old and confirmed entropion will probably require to be treated by a V-shaped excision of a part of the whole thickness of the lid: the cut surfaces being afterwards brought together, and adapted with entomological pins and silk twisted around them. Ectropion generally occurs in the lower lid; entropion (in the numerous cases in which there is thickening and perhaps trichiasis) generally in the upper lid, being there artificially produced. Ectropion from deficient power, or paralysis, of the orbicularis, by force of gravity, and entropion from excessive action of the marginal fibres of the same muscle, as explained already, both affect the lower lid as a rule.

They have had perhaps a chronic blepharitis, or Ectropion on some of the lid, which the eversion of the lid, is caused by gravity, has been before.

Code also the lower lid is less frequently affected, probably because of its being more exposed than the upper.

From abscesses generally of the thickness of bone, which had been a very deep fissure in the lid, and in some cases 3 wounds, were made.

At the time of the action, muscular spasm, single, or double, in the muscular entropion, in some cases of entropion, or lidemia, or which the lid is looked upon when they have been turned out.

It has been said that a weak orbicularis induces a passive entropion; and also that a removal of some too powerful and active fibres of the same muscle, next the lid's margin, will cure many trifling cases of entropion. Severe cases of old and confirmed entropion will probably require to be treated by a V-shaped excision of a part of the whole thickness of the lid: the cut surfaces being afterwards brought together, and adapted with entomological pins and silk twisted around them. Ectropion generally occurs in the lower lid; entropion (in the numerous cases in which there is thickening and perhaps trichiasis) generally in the upper lid, being there artificially produced. Ectropion from deficient power, or paralysis, of the orbicularis, by force of gravity, and entropion from excessive action of the marginal fibres of the same muscle, as explained already, both affect the lower lid as a rule.

OPERATIONS ON THE TEAR-PASSAGES. In any case in which, without any special exciting cause, the tears are found to run down the cheeks, this state of things must be remedied as soon as possible, or it aggravates itself. In the first place, in operating here, we have to ascertain, first, if the lower punctum be rightly placed in contact with the globe of the eye; second, if it be patent; thirdly, if the canaliculus or nasal duct be obstructed. Seldom, if the punctum be averted from the globe, will it be enough to restore its right position. Whilst disused, it has become permanently too narrow. If it be everted a little, it will be enough that the punctum be divided, so that the tears may reach the slit-shaped artificial opening. If it be closed, or too small, it must be slit up; and if the canaliculus or nasal duct be obstructed, it must be thenceforth repeatedly probed.

Among the preliminary "special exciting causes" of an overflow of tears, besides grief and casual external stimulants, such as peat-smoke, we must not omit to search for eyelashes, or other foreign bodies, in or upon the conjunctiva. If there be intolerance of light, there is generally an equal amount of lacrymation when the eyes are exposed to light. Both are excessive in the common conjunctivitis of weakly children. Probably, even though the cause of the weeping, be but temporary—swelling of the parts near the orifice, during conjunctivitis, or abscess of the margin of the lid, everting the punctum—it will be best to slit the inferior canaliculus. And as to the slitting operation,

if such patients are not too feeble, and make an action use of their orbicularis muscles in such a case they may perhaps have been a spasmodic entropion instead of passive entropion.

SLITTING THE PUNCTUM AND CANALICULUS.—In any case in which, without any special exciting cause, the tears are found to run down the cheeks, this state of things must be remedied as soon as possible, or it aggravates itself. In the first place, in operating here, we have to ascertain, first, if the lower punctum be rightly placed in contact with the globe of the eye; second, if it be patent; thirdly, if the canaliculus or nasal duct be obstructed. Seldom, if the punctum be averted from the globe, will it be enough to restore its right position. Whilst disused, it has become permanently too narrow. If it be everted a little, it will be enough that the punctum be divided, so that the tears may reach the slit-shaped artificial opening. If it be closed, or too small, it must be slit up; and if the canaliculus or nasal duct be obstructed, it must be thenceforth repeatedly probed.

Among the preliminary "special exciting causes" of an overflow of tears, besides grief and casual external stimulants, such as peat-smoke, we must not omit to search for eyelashes, or other foreign bodies, in or upon the conjunctiva. If there be intolerance of light, there is generally an equal amount of lacrymation when the eyes are exposed to light. Both are excessive in the common conjunctivitis of weakly children. Probably, even though the cause of the weeping, be but temporary—swelling of the parts near the orifice, during conjunctivitis, or abscess of the margin of the lid, everting the punctum—it will be best to slit the inferior canaliculus. And as to the slitting operation,

if such patients are not too feeble, and make an action use of their orbicularis muscles in such a case they may perhaps have been a spasmodic entropion instead of passive entropion.

SLITTING THE PUNCTUM AND CANALICULUS.—In any case in which, without any special exciting cause, the tears are found to run down the cheeks, this state of things must be remedied as soon as possible, or it aggravates itself. In the first place, in operating here, we have to ascertain, first, if the lower punctum be rightly placed in contact with the globe of the eye; second, if it be patent; thirdly, if the canaliculus or nasal duct be obstructed. Seldom, if the punctum be averted from the globe, will it be enough to restore its right position. Whilst disused, it has become permanently too narrow. If it be everted a little, it will be enough that the punctum be divided, so that the tears may reach the slit-shaped artificial opening. If it be closed, or too small, it must be slit up; and if the canaliculus or nasal duct be obstructed, it must be thenceforth repeatedly probed.

Among the preliminary "special exciting causes" of an overflow of tears, besides grief and casual external stimulants, such as peat-smoke, we must not omit to search for eyelashes, or other foreign bodies, in or upon the conjunctiva. If there be intolerance of light, there is generally an equal amount of lacrymation when the eyes are exposed to light. Both are excessive in the common conjunctivitis of weakly children. Probably, even though the cause of the weeping, be but temporary—swelling of the parts near the orifice, during conjunctivitis, or abscess of the margin of the lid, everting the punctum—it will be best to slit the inferior canaliculus. And as to the slitting operation,

if such patients are not too feeble, and make an action use of their orbicularis muscles in such a case they may perhaps have been a spasmodic entropion instead of passive entropion.

SLITTING THE PUNCTUM AND CANALICULUS.—In any case in which, without any special exciting cause, the tears are found to run down the cheeks, this state of things must be remedied as soon as possible, or it aggravates itself. In the first place, in operating here, we have to ascertain, first, if the lower punctum be rightly placed in contact with the globe of the eye; second, if it be patent; thirdly, if the canaliculus or nasal duct be obstructed. Seldom, if the punctum be averted from the globe, will it be enough to restore its right position. Whilst disused, it has become permanently too narrow. If it be everted a little, it will be enough that the punctum be divided, so that the tears may reach the slit-shaped artificial opening. If it be closed, or too small, it must be slit up; and if the canaliculus or nasal duct be obstructed, it must be thenceforth repeatedly probed.

Among the preliminary "special exciting causes" of an overflow of tears, besides grief and casual external stimulants, such as peat-smoke, we must not omit to search for eyelashes, or other foreign bodies, in or upon the conjunctiva. If there be intolerance of light, there is generally an equal amount of lacrymation when the eyes are exposed to light. Both are excessive in the common conjunctivitis of weakly children. Probably, even though the cause of the weeping, be but temporary—swelling of the parts near the orifice, during conjunctivitis, or abscess of the margin of the lid, everting the punctum—it will be best to slit the inferior canaliculus. And as to the slitting operation,

if such patients are not too feeble, and make an action use of their orbicularis muscles in such a case they may perhaps have been a spasmodic entropion instead of passive entropion.

if such patients are not too feeble, and make an action use of their orbicularis muscles in such a case they may perhaps have been a spasmodic entropion instead of passive entropion.

it may quite safely be done in any case, even if only temporarily, required; for, if it do no good afterwards, it does no harm, and the imperfection of the punctum seems to be of no more serious importance than is that of the pupillary aperture after an iridectomy that was needed and then done. As the lower lid is of the two the most subject to ectropion, so also it seems that the lower punctum is the more frequently everted, obstructed, or obliterated. Gravity is perhaps concerned in both. The Surgeon's attention is seldom called to the upper punctum; if it be too small, altogether absent, or abnormally placed, perhaps he is not called on to discover the fact; but, on examination, the punctum is generally found to be in right position and patent, and yet insufficient to prevent lacrymation when the lower punctum, to which the tears gravitate, is not fit to receive them, or the canaliculus and nasal duct to convey them away. If the lower punctum be so much everted that for any length of time it is dried, it probably becomes narrowed, and would not carry away the tears, even if the ectropion were remedied and the punctum again moistened.

*Operation.*—The patient is seated in a chair, in a good light, with his head thrown back, a towel over it, and resting on the chest of the operator, who is standing behind him. A finger or the thumb of the left hand is placed lightly on the lower and outer part of the skin of the lower lid, which is drawn forcibly down and outwards, and fixed by pressure on the malar bone sufficient to overcome the force of the orbicularis. If the punctum be not everted, so that it may be fairly seen, it is well exposed to view by slight traction with another finger on the skin of the inner part of the lower lid, drawing it downwards a little and fixing it in that position. If the skin of the lower lid be wet with

tears or greasy with ointment, it should be first of all wiped dry; or a corner of the towel may be required to be applied between the fingers and the eyelid. The knife employed is very narrow, and (about an inch in length altogether. It ends in a small probe, of about a line in length, with a slightly bulbous extremity, bent somewhat towards the cutting edge (Fig. 452, b). It is held with the probe-point turned downwards and directed into the punctum; and, when the Surgeon is sure of its being in the right position, some little force may be employed, if necessary, for its passage through the punctum. If the punctum be quite obstructed or disguised, it is well to be as sure as possible that the knife is rightly directed; if little pits be made in the soft skin or conjunctiva with the probe-end, it is so much the more difficult afterwards to make sure of the real position of the punctum. A minute depression, made oval by traction on the skin of the lid, will be detected in the right anatomical position of the punctum, even if it be quite impervious to the tears. The right position may be judged of by relaxing for an instant the dragging force, and, if the lid be bathed in tears, it may be wiped dry, and a very little quantity of the tears may be detected lying in the natural pit or oozing from it. The probe-point being within the punctum, the knife is turned half-round, so that the cutting edge is directed upwards and towards the nose, and the probe-end, which is not in a line with the rest of the instrument, is directed in that which, anatomically, is known to be the direction of the canaliculus. This is then slit up, as far as the probe end will let the knife go, towards the nose, or, at least, well into that part of the palpebral conjunctiva in which the tears

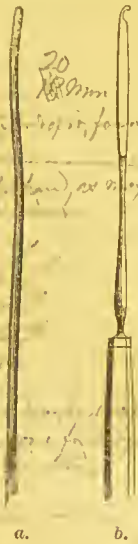


Fig. 452. — a. Bowman's Probe (No. 6) for Nasal Duct. b. Weber's Knife for Slitting Canaliculus.

*Obstruction in the lower part of the canal.*

*the probe is held in the lower part of the canal.*

*a may injure the soft part of the lid.*

*a little force is used.*

*the angle is preserved.*

*X Let the probe be introduced into the canal and smaller the end of the probe is directed towards the nose.*



ABSCCESS OF THE LACRYMAL SAC. 11

habitually lie. The nasal duct may now be probed if necessary. If a little clot of blood lie between the edges of the wound, it is no disadvantage, as it will hinder their reunion. A day or two after the operation, a probe should be passed along forcibly between the edges of the wound to tear through recent adhesions, if they have formed. After this, the open channel will be patent; perhaps not throughout the extent of the incision, but sufficiently far from the punctum to gain all the advantages to be desired of the operation, whether for the admission of tears to the sac and nasal duct, when they are in a healthy state, or for the entry now and then of a probe to be passed along the latter channel if it be obstructed. A small piece of the inner lip of the slit-up canaliculus has been sometimes removed with advantage, when there is eversion of the edge of the lid of an amount and kind which would suggest it. It is easily done, the lid being fixed and drawn down and outwards, with forceps and scissors.

The upper punctum seems to be alone generally insufficient. I do not remember to have slit it up usefully but once, in a case (Ophthalmic Hospital Reports, vol. iii. p. 4) in which the lower orifice could not in any way be found in the dried mucous membrane. The upper punctum was in no way abnormal, and, when slit, I passed a curved probe by it into the sac and back by the lower canaliculus so as to make it emerge at the lower punctum. Then the lower punctum could be slit as usual, and the case was cured forthwith. The upper punctum and canaliculus, even if slit, unfortunately do not make a convenient way for the probing of the nasal duct, because of the projection of the brow; and the upper channel alone, even if rightly placed and patent, does not prevent lacrymation, or at least very often fails.

In acute inflammation or abscess of the lacrymal sac, the lower canaliculus must be slit, and the matter, if any, thereby let out on the conjunctival aspect of the lid, or evacuated with gentle pressure steadily made with two or three of the fingers over the sac. A new difficulty in this case presents itself in the firm swelling of the soft parts of the neighbourhood of the sac, which makes it very difficult to obtain a view of the punctum so as to introduce the probe-ended knife. This may generally, however, be done by pressing the point of a finger or the end of the handle of a scalpel into the œdematous tissues just outside the right position of the punctum, so as to evert it, although the whole lid cannot be everted or drawn aside. An abscess of the lacrymal sac, if neglected, will open through the skin, and leave a permanent scar, but in no case should it be opened externally, unless an external opening should be plainly inevitable, and even then the slitting the canaliculus and probing the nasal duct must be done as before. A fistula lacrymalis is understood to mean a permanent external opening, leading down to the lacrymal sac, not to the gland. It is not an uncommon result of neglect of obstruction of the nasal duct; inflammation of the sac arises, and goes on to suppuration; and, this being neglected, the abscess opens externally through the skin; the pain being relieved, the disease is probably still neglected, and a fistulous opening is established. A scar cannot then be avoided; but a fistula in this situation may generally be induced to heal, if the nasal duct be diligently probed and the natural outlet of the tears re-established. Whilst there is discharge, it may be well, by the use of a small India-rubber bottle syringe introduced by the fistulous opening, if it have not begun to contract, or by the slit-up canaliculus, to inject tepid water or astringent lotions from time to time.

Probing the Nasal Duct.—The normal punctum admits only so very small a probe, that, when the nasal duct is in any way obstructed, it must be slit up as described. Thenceforward a sufficiently large probe can be passed, when it is

Handwritten notes in the right margin, including phrases like "small", "fixed", "and drawn down and outwards", "and canaliculus", "the nasal duct", "the sac", "the lid", "the conjunctival aspect", "the soft parts", "the neighbourhood of the sac", "the fistulous opening", "the slit-up canaliculus", "the nasal duct", "the natural outlet of the tears", "the discharge", "the contraction", "the astringent lotions", "the tepid water", "the India-rubber bottle syringe", "the fistulous opening", "the small punctum", "the normal punctum", "the slit up as described", "the sufficiently large probe", "the passed, when it is".

Vertical handwritten notes in the left margin, including "one eye", "the upper punctum", "the lower punctum", "the canaliculus", "the sac", "the lid", "the conjunctiva", "the soft parts", "the neighbourhood of the sac", "the fistula", "the fistulous opening", "the slit-up canaliculus", "the nasal duct", "the normal punctum", "the slit up as described", "the sufficiently large probe", "the passed, when it is".



probe in for a short time, as may be done for the strictures of the canaliculus above described. It should be removed when it has passed all along the duct. It must be passed again many times, at intervals of a few days, and the size, up to No. 6, increased, if at first it have not been possible to pass the largest probe. If, after the obstruction has been remedied, as very often happens, the stoppage again take place (the punctum and canaliculus are now always patent), recourse must be again had to the probing. The smaller-sized probes are liable to be caught in folds of the mucous membrane and to make false passages; and No. 6 (or 5 or 4) by a little pressure in the right direction, and with all due precautions, will almost certainly pass. If the probing finally will not cure the obstruction, a style, introduced by the slit canaliculus, must be worn for a time. It consists of a silver wire, of the size of the No. 6 probe, two inches or less in length, and abruptly tapered into half an inch of about the size of the No. 2 or 3 probe; this end is bent down when the style has been introduced.

SQUINT-OPERATIONS.

In these operations the object is, by dividing the tendon of the rectus muscle which produces the Strabismus, to cause it to become attached to the globe of the eye at a point behind its natural insertion into the sclerotic. Then the muscle regains and retains the power of moving the eye, but in a diminished degree, so as, usually and without any special exertion, to place the eye in a position parallel to that of the other. The first point in diagnosing a fit case for tenotomy in squint cases is to ascertain that all the muscles of the eye act, and that there is no paralysis of any of them. Then, again, an operation should not be performed in any case in which the squint is not confirmed, where sometimes there is no degree of squint; in such a case, spectacles should be tried. Convex glasses (for hypermetropia) are very often needed in squint cases to remedy a slight degree, or, at least after the operation, to correct the pre-existing error of refraction. The hypermetropia is the cause why most of the patients who squint have begun to do so at the age at which children have learned to read and observe near objects closely. Very young children are therefore very rarely subjects for squint-operation. And even if the case be one of a confirmed squint, the operation (in a very young child) may be deferred, if the vision of neither eye be impaired. A large majority of these cases are of convergent strabismus, requiring division of the internal rectus tendon or tendons. Of 307 primary operations for squint, at the Royal London Ophthalmic Hospital, in Moorfields, in 1871, 275 were for convergent, and 32 for divergent strabismus. The superior or inferior rectus tendons are very rarely divided. A squint downwards is hardly ever seen but in hydrocephalus, of which it is supposed by some to be pathognomonic; it is, in these cases, of both eyes, and only occurs at intervals.

To ascertain the existence or the degree of squint, the patient is placed standing before the Surgeon, who observes which eye seems to squint. The Surgeon, if, for instance, the patient's right eye be turned inwards in looking at him, extends and closes the fingers of his right hand, bringing them with the back of the hand to the face of the patient, close up before his left eye, without touching it; then, the patient still regarding the face of the Surgeon, the left eye being shut out, the right eye is everted from its former position and turned out sufficiently to continue the steady gaze of the patient in the face of the Surgeon. The Surgeon now removes his hand quickly from before the left eye, and this is observed to be turned inwards, as the right was; probably it now quickly adjusts itself, and, as at first, the right is again inverted. Or the

*the eye... being used... the patient... observed... inverted...*

Surgeon, if the right eye do not now seem to be again turned in, uses his other hand, and excludes, without closing, the patient's right eye, to see, as the patient is always looking steadily in his face, if the other will now seem to correct itself; and so he proceeds, successively and alternately, to confirm his diagnosis. It is very improbable that, if there be some degree of convergent strabismus, even though not constant but recurrent, it will not be manifested when the patient is under the excitement of a formal examination, and is regarding a rather near object, the face of the Surgeon. If there be no squint, and the previous diagnosis were in error, whichever eye is shut out in the way described, the other will not move or change its position, for it continues to look at that at which it was desired to look.

If we desire to estimate exactly the *degree* of strabismus, the patient is desired to look straight before him at any object. A little mark is then made on the skin near the edge of the lower lid of the wrongly directed eye, at a point vertically corresponding with the outer (or inner) edge of the circumference of the cornea. Then the other eye of the patient is closed with the hand; and the patient, without turning his head, is desired still to regard the same object. The squinting eye is then righted; and another mark, again corresponding to the same part of the margin of the cornea, is made on the lower lid. Then the distance between the two marks is measured, and the squint is said to be of so many lines. If, in a case of convergent squint, the interval be of as much as three or four lines, it is probably advisable that the tendons of both the internal rectus muscles should be divided at once, rather than that alone of the eye only ostensibly squinting. In the more common and less degrees of convergent squint, it is best at first in each case to divide only the internal rectus tendon of the eye habitually inverted, and to divide the other afterwards only if the first operation should prove to be insufficient. To determine which eye is to be operated on, close attention to the patient, for a short time, covering neither eye, will generally be enough; or both eyes of the patient may be repeatedly covered for a minute and uncovered with the hand of the Surgeon, so as better to observe which eye is habitually turned in. As to repeated divisions of the same internal rectus tendon, when the eye has persistently remained inverted, experience is rather unfavourable; but if without it the defect be not remedied, it must be done, supposing, of course, that the opposite internal rectus tendon has been cut.

OPERATION.—The operation for squint is thus done. A wire-speculum (Fig. 453 *a*) is inserted between the lids, which are thus widely opened. A small fold of the conjunctiva is then seized with toothed forceps with fine points (Fig. 453 *b*), just below and a little in front of the insertion of the rectus tendon to be divided; with straight and rather blunt-pointed scissors (Fig. 453 *c*), this little fold is cut through horizontally; the forceps is then inserted, closed, rather deeply in the wound, and a fold of subconjunctival tissue, fascia, &c., is pinched up close to the sclerotic, and divided with the scissors on its sclerotic side. Now, the forceps still holding that which was last taken up with it, the points of the scissors being still pressed against the sclerotic, and each time very little opened, a succession of little snips is made, the scissors being pushed backwards to some little distance beyond the insertion of the rectus tendon and below the muscle. When none of the fascia in this tunnel-like opening remains uncut, when it offers no more resistance, the scissors are withdrawn, and, remembering the direction of the deep little opening just made, and observing that the eye has not changed its position, or, if it have moved, allowing so much for the change of position, the strabismus-hook (Fig. 453 *d*) is quickly inserted and carried directly backwards through the length of the opening in

the conjunctiva and subconjunctival tissues, and then, *the point being always kept close against the convex sclerotic*, the handle is depressed, and the hook passed upwards under the tendon of the muscle to be divided, and brought forwards up to its insertion. The points of the scissors are then carried along the sclerotic side of the hook, and opened a little, so that one blade passes with the hook under the tendon, and the other in front of it. This blade will pass beneath the conjunctiva without penetrating it, or if it be too closely adherent, the two blades of the scissors, closed, may, before dividing the tendon, be made to open a way in front of the insertion of the tendon. The tendon is then cut

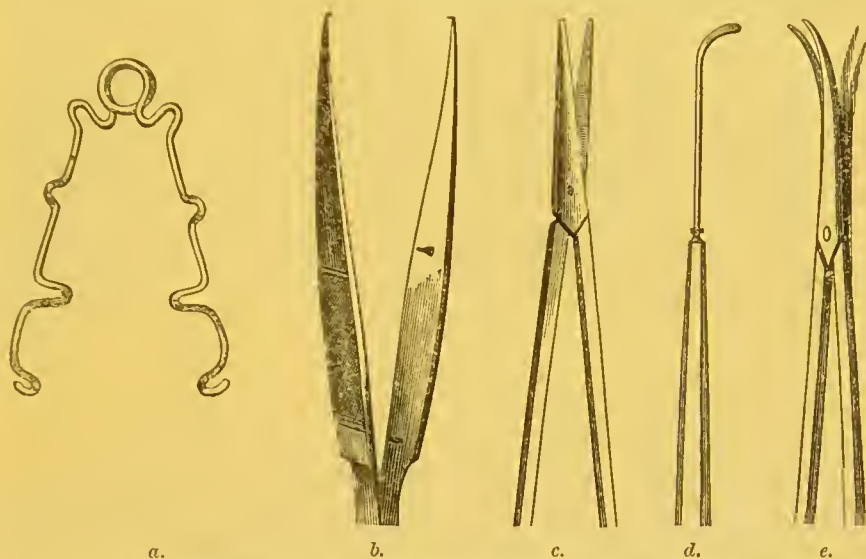


Fig. 453.—*a.* Wire-Speculum. *b.* Toothed Forceps with Fine Points. *c.* Straight Scissors. *d.* Strabismus-Hook. *e.* Scissors for Dividing Optic Nerve in Extrinsic of the Eye.

through ; the hook being at the same time everted a little to allow one blade of the scissors to pass between it and the sclerotic. The scissors' blades are opened as little as may be required, so as to prevent any unnecessary disturbance of the parts, or tearing open of the external opening. An inexperienced operator is liable to be misled by a want of knowledge of the feel of the sclerotic, when it is reached as the hook is passed along beside the globe upon it ; or by a fear of keeping close to the globe of the eye. There is no fear, especially for an anatomist, of cutting into the sclerotic. The tendon, before it is lost in the sclerotic, lies for some, or all, the distance along the surface of this membrane ; so that, to insert a hook beneath it, the end of it must be brought to bear at a point inferior to and behind the insertion ; and then, being steadily pressed against the sclerotic with some little force, it must be carried upwards and backwards and then a little forwards. In these operations for the division of tendons we must also recollect how wide is the insertion, and at what distance from the margin of the cornea ; and in this they vary a little. The opening in the conjunctiva should be made no larger than will be enough. The conjunctiva, when the tenotomy is completed by this method, prevents the eye from being carried unrestrainedly in the opposite direction. The object is not merely to divide the tendon ; but, according to the degree of distortion, the operator will separate, more or less, the tendon and muscle from its surroundings. In an extreme case, any minor tendinous insertions lying beneath the chief portion of the muscle concerned must be searched for and divided ; while, in trifling cases, these, or at any rate the areolar tissue in con-

nection with the tendon, should be undisturbed. It is not advisable, however, in extreme cases, that the operation should be made to resemble the old squint-operation, by dividing the conjunctiva over the insertion of the tendon. If this be done in internal strabismus, it leads to retraction of the caruncle and the plica semilunaris, and a staring look of the eye, although it be made to act in a parallel direction with the other. To obviate the difficulty of an extensive *accidental* rent of the conjunctiva during the operation, especially if it seem to be thin and liable to be torn open, the forceps, instead of a second time being made to grasp the parts to be divided, may at first be made to seize the subconjunctival tissues together with the conjunctiva in a fold in a radiating direction from the centre of the cornea, and the conjunctival opening made far back from the margin of the cornea; the scissors also should be less blunt-pointed than those figured, and by pressing their separated points towards the eyeball firmly before closing them, to make the division, the operation may be completed without using the forceps in the wound at all. In extreme cases, the corresponding tendon of the opposite eye certainly should be divided. The test of complete tenotomy in these cases is that, when the hook has been passed so that if any fibres were uncut they would be caught in it, the concavity of the instrument can be brought up to the convex edge of the cornea under the conjunctiva, and will remain there passively, without any dragging force.

As squint-operation is a painful one, at any rate as compared with most eye operations, it is usual to give an anæsthetic; but, during and after the inhalation, the muscles of the eyes do not act together as they would without its having been used, and, at any rate, at such times the patient cannot be made to attend well to the Surgeon's wishes in directing his eyes. Children with or without chloroform or bichloride of methylene will not give us this assistance, and they therefore at least should always have the anæsthetic.

The operation being over, and it being found that the tenotomy has been satisfactorily done, a piece of lint wetted with cold water, and a round hollow sponge or some wool dipped in the same, are at once tied tightly over the eye, with a strip of common bandage fastened behind the opposite ear in a knot. In six hours the lint, sponge, and bandage may be left off (the fear of "black eye," or much ecchymosis, being passed), the two eyes may be uncovered and brought into use together (for distant objects as much as possible), and the eyes only bathed with lukewarm water as often as the patient may desire it.

Tenotomy, as concerns the muscles of the eyes, is hardly ever done but for the cure of one or other of the kinds of squint actually existing. It is, however, desirable to divide the external rectus tendon in some cases of muscular asthenopia (insufficiency of the internal rectus muscles) as well as of external strabismus; and several of the tendons (sometimes in the same eye of the same patient) have been divided in cases of oscillating globes; and the upper, inner, and outer tendons have been cut when an artificial pupil has been made necessarily at the upper margin of the cornea, so as to weaken the opponents of the inferior rectus.

#### OPERATIONS ON THE EXTERIOR OF THE GLOBE.

**PTERYGIUM.**—This is not a common disease in England. The cases which we have seen have been in adult men, sailors, perhaps foreigners. The disease consists in an hypertrophy of some portion of the ocular conjunctiva and subconjunctival tissues, consequent upon some long previous chronic irritation or inflammation; and as the vessels of this mucous membrane pass to or from the centre of the globe in front, radiating in all directions, it has

a triangular shape, of which one angle is at or approaches to the centre of the cornea, just as much as the vessels of a chronic ulcer of the cornea following phlyctenular ophthalmia, which follows one of the exanthemata, have a wide circumferential origin, and are definitely bounded on each side, ending as it were at one point or apex—the ulcer itself. So it is in what has been called “fascicular keratitis,” though the vessels are not collected in a bundle in it, but converged.

Pterygium is to be got rid of, because it will always steadily advance up to the centre of the cornea, and so, to some extent, interfere with vision; and very much too, if, as is not uncommon in these cases, more than one pterygium should form in the same eye, and, advancing from different directions in the circumference, meet in the centre, towards which the apex of the growth is always directed; or if, as is not common, a pterygium should advance from below upwards. The growth is also to be removed, because it is a conspicuous deformity, easily remediable, so that at least only an irregular whitish scar is left in its place. A pterygium should be removed in any stage of its growth. At first, it is but little redder than the surrounding conjunctiva, and hardly at all raised above the conjunctival surface. It has then been called a “membranous pterygium.” Afterwards it becomes very much more vascular and raised above the surface—“fleshy pterygium.” In either case an operation is called for. No other treatment is of any use.

Pterygium has been removed by dissecting up the growth from apex to base, transplanting the apex of the flap thus formed into an incision made along the lower part of the ocular conjunctiva beneath the lower lid, and fixing it with sutures in this position. I do not remember that in any of the cases in which I operated in this way the disease returned; but excision of the whole growth more effectually removes the deformity than merely transplanting it; and total abscission is the commonly adopted practice nowadays. Nevertheless, even when carefully removed, pterygium is apt to return; and hence it is important in operating to remove the whole thickness of it, down to the sclerotic and cornea.

*Operation.*—An incision is made with a scalpel through the conjunctiva, along the borders of the growth, whilst put on the stretch by the eye being drawn with forceps in the opposite direction, if necessary by an assistant; and then with a pair of forceps, with rather long sharp teeth, the whole width of the pterygium is taken up, between the two lines of incision in the conjunctiva, at about the middle of its length, and raised sufficiently to allow the scalpel to be thrust beneath it with the edge towards the cornea. The growth being well raised from the surface of the globe, and the traction made in the direction opposite to the place of the pterygium being relaxed, the scalpel is carried onwards, close to the surface of the cornea, up to the centre or as far forwards as the growth extends. The whole is shaved off at once; the flap is then seized and raised, and dissected off the surface of the sclerotic, and finally removed altogether as far back as it seems to extend at its base, near the junction of the ocular and palpebral conjunctivæ. If any small portions of the pterygium have been left, they should be seized and shaved off the surface of the cornea or sclerotic. The growth should be removed quite up to its margins and to its apex, as far forwards on the cornea as it extends. It may everywhere be raised with forceps from the firm structures, cornea and sclerotic, beneath. If a fine shaving of sclerotic or cornea be taken off, it is not of the serious importance that has been suggested; but of course it should not be done. All soft parts, where the pterygium is situated, should be dissected off the sclerotic and cornea; and if the knife be held flat to the surface of the globe

of the eye, there is no fear that an incision will be made actually into the globe.

After the operation no special treatment is required; but, by using warm water to bathe the eye, great cleanliness is maintained; and, if the movements of the eyes cause any pain in the eye operated on, they may be tied up, and so kept at perfect rest for awhile.

**REMOVAL OF FOREIGN BODIES EXTERNAL TO THE EYE.**—A foreign body, such as a particle of dust or of coke, superficially sticking in the eye, is generally to be found embedded in the cornea. The cornea is the most prominent part of the eye; and if a foreign body should hit the sclerotic conjunctiva, it is probably somewhat obliquely, and so it may glance off at once and not remain there. It is probably soon dislodged from the sclerotic conjunctiva, as it is loose and easily moved, and is washed away in the tears. It is often very difficult to see the very small foreign bodies which lodge in or upon the cornea, especially if the iris be dark-coloured, as they are also generally. In order to detect the presence of a foreign body, the Surgeon must open widely the patient's eye in a good light and bid him look in various directions or on all sides, successively; when, if the iris be light-coloured, the foreign body is probably soon detected as a dark speck, and may be removed forthwith. If the foreign body be light-coloured or transparent, its situation may be detected on the eye itself by viewing the convex mucous surface, in all its parts successively, with the light of the window reflected from it, and then, at this point in particular, the light is irregularly reflected as it is in case of a simple abrasion, or loss of substance, when there is no foreign body. If it be not thus detected, the lower lid must be pulled down with a finger placed on the skin of the lid, and the patient desired to look very much upwards, so as to expose completely the palpebral and ocular conjunctival surface of the lower part of the eye. It is, however, more probable that, if the foreign body be under either eyelid, it is the upper one. In this case the Surgeon, standing before the patient, places the end of his forefinger sideways on the lid near its outer edge, without involving any folds of loose skin; and pressing a little on the eye, makes the lid slide downwards, as far as possible, over the lower lid. The lid (not the lashes) is then seized firmly by the end of the thumb applied sideways; and the end of the forefinger is turned downwards, while the lid is held firmly by the thumb and finger. The lid is thus everted (Fig. 454).

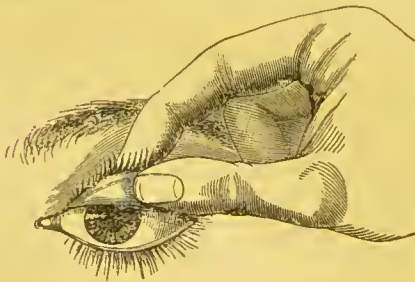


Fig. 454.—Eversion of Upper Lid for Detection of Foreign Bodies.

This is a better plan than using a probe, or a pen laid horizontally on the lid, and then pulling the lid by the lashes over the barrier so as to evert it. The fingers are always available, and the patient is not so much afraid of them as of any instrument. The little operation cannot, however, be done the first time it is attempted. The patient may move back his head just as the turn is to be completed (therefore the head of the patient must be steadied by being placed against the wall, or the

back of his chair, or by the other hand behind it); or the lid is not secured between the finger and thumb before the eversion is attempted; or the lashes only and not the lid are held; or one fears to press the forefinger sufficiently into the eye to effect the eversion. It is very much more difficult if the patient be fat, the eye deeply set, and the orbicularis strong, or the lid thickened



and contracted—inclined to be inverted—by old results of ophthalmia. The upper lid being everted, it is held so and pushed upwards as much as possible with the thumb against its edge; and, the patient being desired to look very much down, we expose nearly the whole of the upper palpebral and ocular conjunctivæ. If the foreign body be not now seen, it is well to pass the tip of the forefinger lightly over the everted palpebral conjunctiva, as in this way the foreign body may perhaps, if transparent, be felt; or we may pass the spoon-end of a common probe quite up to the sulcus, if it cannot be seen, and along between the upper palpebral and ocular conjunctivæ, to catch the foreign body if it should be there. If it be not now found we may again examine the cornea, for it is here that nearly all foreign bodies in the eye are found; and the oblique illumination with the ophthalmoscope, using a second convex lens as a magnifier, may be serviceable in this examination. Not unfrequently a larger foreign body, such as a small button, or a husk of corn, purposely or accidentally introduced under the upper lid, has passed beyond the upper edge of the cartilage, and so is retained for months or years, until the persistent slight irritation leads to its detection and removal. Therefore, in doubtful cases, as above recommended, the spoon-end of a probe should be used.

To avoid error in diagnosis, it is always well to inquire if the patient remember the time at which the foreign body entered the eye, when he has the sensation of an existing foreign body, for there are many irregularities of the surface of the palpebral conjunctiva, which, in its movements, give the sensation as of a foreign body when there is none. Conjunctivitis especially is a cause; and if there be no such cause, and the patient recollect no particular time at which he first felt the foreign body, and “something got into his eye,” we must look for some little tumour, or a somewhat inverted eyelash or other persistent cause. A patient may have the sensation as of a foreign body in the eye when it is there no longer, but has left, perhaps, a slight abrasion.

A foreign body in the cornea is best removed with the end of a little instrument which is like a piece of wire flattened at the end, and with a round edge, but little sharpened, like a “spud.” A piece of wire, beaten out at the end, is the instrument made for themselves, and used by some one of their number, by the workmen in some of the large factories. With this, the lids and the eye itself being held open and fixed with the fingers, the foreign body is turned out of the hollow in which it is embedded. Sometimes, if it be very deep in the cornea, a sharp-pointed or cutting instrument must be used.

There is a class of cases by no means common, which may be considered together with foreign bodies in or upon the cornea, for the offending substance is quite superficial to the cornea and keeps up irritation. It appears as a perfectly opaque, dense, whitish opacity on the front of the cornea, unlike leucoma in its *perfectly definite* outline, and in being very superficial and *dead-white* in appearance. There is also some injection of the eye, which there is not generally in cases of circumscribed leucoma—the dense corneal opacity left long after the inflammation before it. The foreign substance is deposited in some hollow of the cornea, an excoriation, abrasion, or ulcer, probably after using some lotion of acetate of lead, which is too often applied by patients for all eye-inflammations indiscriminately. It must be picked out of the little hollow, like any other foreign body; and if it be in a layer beneath the epithelium, this must be scraped off, and then the deposit will be found immediately beneath it; and in these cases, with some difficulty, little by little, in broken flakes or fragments, it can be removed with the point of a knife, or, with the edge of it held flat, it may be shaved off. It should be, at

all events, altogether removed; for, if it should be succeeded by a dense leucoma, the latter is of no importance beyond the fact of the opacity of the cornea; whereas the former is somewhat equivalent to a foreign body also. But it will not probably be followed by a leucoma; the cornea will become and remain tolerably or quite clear when this superficial opacity is removed from its surface. A little olive oil is dropped upon the cornea, and the eye bandaged with belladonna lotion or fomentation, until the wound has healed and the epithelium is restored.

**TAPPING THE CORNEA.**—This little operation often does much good, in cases generally only medically treated, locally and generally. When there is pus between the layers of the cornea (*onyx*) or in the anterior chamber (*hypopyon*), or in painful ulcer of the cornea without suppuration, it often acts like a charm; some of the aqueous humour and pus are evacuated, the pain disappears, and the chronic ulceration of the cornea begins to heal kindly. The operation should be adopted in a greater number of cases; but it must be done properly without wounding the lens or iris, or doing anything but just to make a small clean puncture obliquely into the aqueous chamber and so letting the fluid contents leak away quietly, and not very rapidly. In *onyx* and *hypopyon*, the tapping, to be efficacious, may require to be repeated at short intervals; and if it fail, as it will probably, if it do not from the first seem to have been beneficial, iridectomy must be done, and will probably succeed. Iridectomy is often performed at once in these diseases; but, in most of the less serious cases, with no increase of tension of the eye, the minor operation of tapping is all-sufficient.

*Operation.*—A spring (stop) speculum to keep open the lids, and a fine-ended and two-toothed forceps to steady the eye and hold it down, may be and are generally employed (Fig. 453, *a* and *b*). But, unless pressure on the globe would endanger the good result, they are unnecessary, and are liable to alarm the patient. In performing the operation, the upper lid should be raised, and the end of the forefinger of the left hand laid horizontally and rather flat upon the edge of the lid and on the globe above the cornea, taking care here, as in other eye-operations, not to touch the eye with the finger-nail. The lower lid is similarly depressed and held down

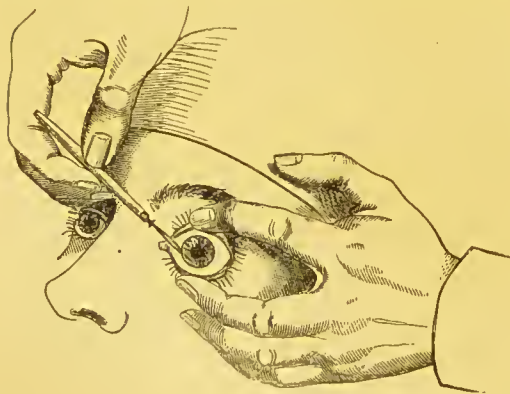


Fig. 455.—Tapping the Cornea.

with the middle finger of the same hand, on the eyeball below the cornea. The two fingers are separated as widely as necessary, and such pressure is exerted upon the globe backwards as will allow no opportunity of closing the lids and of the orbicularis regaining its power of action (Fig. 455). The front of the globe is now very prominent, and the eye is at least as much under control as if it were held with forceps. With an ordinary broad needle, flat forwards, held in the right hand, the puncture is made in the cornea near the margin, the point being soon directed obliquely downwards and across the anterior chamber, as if about to make a counter-puncture at one-third of the circumference. As the eye tends to roll upwards, the needle, when directed downwards, cannot wound the lens. In this way

the blade never passes the pupillary margin; its point is always in front of the iris, never of the lens (Fig. 455). As soon as the broadest part of the blade has entered the cornea, it is partly withdrawn, and, cutting downwards a little meanwhile, the point of the needle is again directed to the centre of the anterior chamber. As the opening is now a little larger than the blade, this can be rotated a little; and, when it is held in this way, the aqueous humour or the contents of the aqueous chamber will flow out beside it, more or less slowly, according to the amount of the rotation. As it is almost all evacuated, the pressure of the two fingers, keeping open and steadying the eye, must be a little remitted; probably no great effort at movement will be made by the patient at this time, but, to prevent possibility of accidents, the broad needle, still held flat forwards, should now be brought altogether somewhat forwards, and may thus be used in some degree as a *point d'appui*. The operation done, the needle is quickly withdrawn, and, the fingers being removed, the eye closes. In this brief and simple operation, every precaution must be taken against wounding the lens and making a traumatic cataract. This accident may occur whether the eye be steadied by the finger or by speculum and forceps, either when the needle is introduced, or when the last of the aqueous humour is let out. The operation is attended with little or no pain, even if anæsthesia be not employed; and, if the fingers and one instrument only (the broad needle) be used, the soft parts of the fingers give no pain, and the patient is but little alarmed.

#### OPERATIONS ON THE IRIS.

**ARTIFICIAL PUPIL.**—In this operation a piece of the iris is either removed altogether, *excised* (iridectomy); or, by simple *incision*, an opening is made in the iris-tissue. The term artificial pupil is also applied to any operation by which the natural pupil is displaced and altered in shape and position, as well as to those by which an addition is made to the natural pupil, or those by which an altogether new opening is made in the iris itself.

There are many different directions in which an artificial pupil may be made: (1) central and downwards, or (2) down and inwards, or (3) down and outwards, or (4) inwards, or (5) outwards. The upper lid so much covers the upper part of the cornea and iris, that it is a forlorn hope only when the operation is done any way upwards, as a *direct* means of improving vision (see "Iridectomy for Glaucoma," p. 357).

Artificial pupil, *per se*, is called for in many very different cases.

1. In *Partial Opacity of the Cornea*, with or without iris-adhesions, it is required to make a pupil opposite clear cornea.
2. In *Total Posterior Synechia* (exclusion of the pupil), it is needed to re-establish communication between the anterior and posterior chambers, &c.
3. In *Closed Pupil* (occlusion), it is required to make a pupil opposite clear (uncovered) lens, &c.
4. In *Central Lamellar Cataract*, this operation is performed to bring the pupil opposite clear (non-cataractous) lens.

Next to cataract-operations, those on the iris essentially are those which the ophthalmic Surgeon is most frequently called upon to perform. They made nearly one-fifth of all the operations done in 1871 at the Royal London Ophthalmic Hospital in Moorfields, without reckoning any of the very numerous *preliminary* iridectomies in cataract extraction and other operations. If an operation for artificial pupil be thought of in a case in which the natural pupil is quite obliterated, or where, in any case, even with atropine, an ophthalmoscopic examination of the fundus cannot be had, the Surgeon must first carefully ascertain that the

eye retains perception of light. But, in order that the operation may be likely to succeed in restoring useful vision in such cases, the patient should not only have a perception of light, but should be able, when the other eye is closely covered with the palm of the hand, to readily perceive the shadow of the hand of the Surgeon when it is passed quickly before the light, between it and the eye of the patient, even at a distance of two or three feet. If there be a less degree of vision remaining, if the tension of the eyeball be plus or minus, indications of intraocular pressure, or atrophy, there must have been some deep-seated disease, besides the iritic inflammation, the immediate cause of the obstructed pupil. After estimating the degree to which vision is impaired in the case of proposed operation for artificial pupil, the Surgeon must observe accurately what evidence of past disease he can see with his own eyes, and compare all this with the history of the case. If corneal opacity be the reason why an artificial pupil should be made, the operation must be deferred until, after some months at least, no improvement by progressive clearing has taken place, according to the history of the case, or by the Surgeon's observation, no redness of the sclerotic has appeared around the cornea, and no former operation of the same kind has been attempted. A lad was admitted at University College Hospital for the operation of artificial pupil. He had had keratitis of both eyes some years before, and slight attacks more recently. He had been treated at intervals as an out-patient for a long time, with cod-liver oil and syrup of iodide of iron, &c. He was anæmic, and, apparently, lived poorly. When taken into the Hospital, he had full diet, and he sat, almost blind, by the fire with the other patients. Very soon he could see better, and in a short time the clear marginal part of the cornea was wider. When the operation was performed, a few weeks after his admission, it was remarkable how his corneæ were cleared, after they had been at a stand-still for months, if not for a year previously, according to the patient's own account, and the latter part of the time during which he had been under our own observation.\* Of course, if there be ever any appearance of present, or any history of recent inflammation, any faint diffused nebula of the cornea and slight redness around it, it must be understood that it is not of that external nature with superficial vessels, due to granular lids, an inverted eyelash, or other mechanical means, but an affection of the cornea itself. One can only wait for the cornea to clear as much it will, always from the margin, of course. The general health of the patient must be attended to, and belladonna locally may be of some use, meanwhile, as a sedative and mydriatic.

In any case of opacity of the cornea extending nearly to the margin, and allowing at no part any wider clear space for artificial pupil, the incision of the cornea must be made in the sclerotic-corneal junction and very little obliquely, so that the iris may be drawn out quite up to its outer circumference.

Artificial pupil, if one eye *only* be diseased, is *urgently* required if there be total posterior synechia or numerous adhesions, and should be done, although the performance of the operation is not urgent, *if the patient incline to it*, in any of the other cases, even if the unaffected eye be perfectly sound.

INCISION.—This is an operation not much in use. It is advisable perhaps only when the lens is no longer present, or, at least, is useless and of no account by results of operation or injury, and the iris has prolapsed through the corneal wound; or when the pupil has been obliterated in consequence of iritis, the cornea remaining clear, and, there being no communication between the anterior and posterior aqueous chambers, the iris-fibres bulge forwards all

\* In cases of old hopeless leucomata, at a subsequent time to the operation for artificial pupil, if any such operation be done, the disfigurement may be entirely remedied by tattooing them of a somewhat darker colour than the iris.

round wherever they are not too tightly stretched. When they thus bulge, though a transparent lens may be supposed to exist behind the iris, it may perhaps be *safe* to incise the tense iris-fibres somewhat obliquely; but, in such a case, probably an iridectomy would be a better operation. It is probable, indeed, that mere incision for the formation of an artificial pupil, should be confined to those cataract-cases in which the extraction-operation has been followed by inflammation and closed pupil, with stretching of the iris-fibres. If, in such a case, the Surgeon anticipate inflammation to follow the secondary operation, one simple cut with a broad needle may be rapidly made across the iris fibres. In such cases, too, the iris may be fearlessly incised; there is no transparent lens or no lens to be wounded. The vitreous humour probably protrudes through the opening in the iris; and, if no fresh inflammation be set up, a good pupil may be made, and may remain (Fig. 456). Just after the operation,



Fig. 456.—Incision of Iris.



Fig. 457.—Artificial Pupil after Iridectomy.



Fig. 458.—Pupil after Iriddesis.



Fig. 459.—Iridectomy for Glaucoma.

when the pupil is first made, it will appear, of course, to be good, because the aqueous humour has escaped, and the protruding vitreous body then makes it appear very black and clear.

*Operation.*—The eye being well steadied with wire speculum and forceps, or with the fingers, a broad needle, with a cutting edge not confined to the part near the point, is thrust through the cornea and then through the iris at one extremity of the intended incision, and, as it is withdrawn, it is made further to divide the iris-fibres to the other extremity of the aperture that is to be made.

*IRIDDESIS.*—Before this operation was invented by Critchett, there was an operation for artificial pupil, which consisted in effecting a prolapse of the iris by the cornea, and thus it was hoped an anterior synechia would result; but, by tying the iris externally, it is secured, and cannot return, even partially, within the anterior chamber.

Iridesis makes a regular outlined pupil, of moderate size, largest towards the centre of the cornea (Fig. 458). In these diagrams the cornea is never represented: a central leucoma is supposed to exist in the present instance. The dotted circle shows the place of the pupil before displacement. The operation does not cause bleeding into the anterior chamber, and its subsequent complications. The pupil may be larger or smaller, but not very large; and, as it is made, so it remains definitely. Iridesis has been much in vogue for cataract of that "congenital" form (lamellar and nuclear) in which some layers, or some parts of them, are definitely opaque, if centrally, with a clear marginal part of the lens. This is a stationary form of cataract, and if atropine show a sufficient margin of clear lens, generally behind the iris, we may make there an artificial pupil by displacement and ligature, and let the patient have the use of the natural lens, rather than substitute a glass.

The *Operation* is done thus. The eye being exposed, and held with speculum and forceps, a broad needle is passed through the cornea at that part of the margin towards which it is desired to place the pupil. An assistant then places a little loop of very fine black silk over the opening on the wet surface of the conjunctiva, and leaves it there. To draw out as much of the iris as is required, either

an ordinary silver iris-hook is used, or, if it be desired not to include the whole breadth of the iris to be prolapsed, and the pupillary margin is to be left free, a cannula-forceps is used to seize the iris midway between its greater and lesser circumferences. The part of the iris which is to be secured being now drawn out by the corneal aperture, the assistant, holding in each hand a forceps with broad ends, like those used for pulling out eyelashes, seizes the ends of the ligature, and, when desired by the Surgeon, tightens the loop and leaves it. This he does whilst depressing a little the ends of the two forceps, so as to tie the knot quite close to the cornea; and he is careful not to pull the ligature more one way than the other, lest the iris be dragged on one side, or, being very delicate, and offering no perceptible resistance, it be very easily cut through. The ends of the loop are then cut off close to the cornea, the eye is closed, and both eyes are bandaged. If the knot have been sufficiently tightened, the portion of iris so strangulated and the little hoop of silk will drop off in a day or two; and the iris, meanwhile, has formed an adhesion within in front (anterior synechia).

But by this method of proceeding the *ultimate* results are often very unsatisfactory: the *iris is confined*, and a low chronic recurrent iritis, etc., may be set up, which leads to far worse results than the state of things which the operation was intended to remedy. These artificial anterior synechiæ seem to be as pernicious as are the common iritic posterior synechiæ. We have recently seen many instances illustrative of this disagreeable truth. An excision of iris is a far safer though less attractive operation. If iridesis be ever to be done, we prefer the proceeding with cannula-forceps, seizing the iris midway, and not the pupillary edge, as in this way much less confinement is caused; and when but a *slight* displacement of the pupil will effect the purposes of good vision, iridesis may yet be permissible.

**EXCISION: IRIDECTOMY.**—This operation is especially advisable when a considerable opacity of the cornea leaves only a very narrow marginal part clear: when iritis has caused occlusion of the pupil (Fig. 457), total posterior synechia or very considerable adhesions, which cannot be detached by the use of belladonna, or by operation: when perforating ulcer or other cause has ended in complete or almost complete adhesion of the pupillary iris to the cornea. But in all the cases requiring artificial pupil operation, an excision of iris is in a very large majority the best.

*Operation.*—An anæsthetic is first given, and the eye is kept open and steadied in the usual manner with speculum and forceps. An opening into the anterior chamber, of at least one-eighth of the circumference, is made in the corneal margin with an extraction (Sichel's) knife. If now it should be necessary that the eye be held in order that the corneal wound may be exposed, the forceps to hold the eye is handed to an assistant; and the iris-forceps, closed and held in the left hand, is introduced into the anterior chamber. A sufficient quantity of the iris is seized and drawn out; and, with the iris-scissors laid flat on the surface, it is snipped off close to the cornea. The operation, with extra precautions at the time and subsequently, is described in the next page (see "Iridectomy for Glaucoma").

An artificial pupil should not be very small, as it will more probably become closed by subsequent inflammation, or, if not closed, contracted till it is much too small for useful vision. The iris must be seized with forceps: a hook may tear through rotten or firmly adherent iris, or will draw out too little. No blood should be allowed to accumulate in the anterior chamber, if it can be prevented. No clot should certainly be left between the edges of the wound in the cornea. And, if the iris, close to the part where it has been cut off



corneal junction, or even in the margin of the sclerotic, at the upper part. About one-fifth of the whole iris is removed in the operation. For this purpose, a lance-shaped knife is generally thrust into and across the anterior chamber, and the incision is extended, if necessary, as the knife is being removed; but an ordinary (Sichel's) extraction-knife is much preferable. It cuts better, requiring less thrusting force, and with it the wound in the cornea may be made less obliquely through the coats of the eye, nearer, that is to say, to the greater circumference of the iris, which we want to reach; and the point of the cutting instrument always between the cornea and iris may be kept quite away from the front surface of the lens, instead of being, as when the lance-knife is used, necessarily carried straight across it. In glaucoma, the anterior chamber is very shallow. The point of the knife, which may be held in the right hand for either eye if the operator be not ambidextrous, is introduced in the sclero-corneal junction, at the right extremity of the incision to be made, and carried a little way towards the centre of the anterior chamber; and, when it has well entered this chamber, the cutting edge is directed upwards and forwards, and being thrust onwards steadily, with a firm hand, so as not too quickly to evacuate the aqueous humour, is made to cut, aided perhaps by slight sawing movements up and down, rather vertically (not by making a counter puncture, as some recommend) as far along the extreme margin of the cornea or sclerotic as the length of the incision is to be made, at least one-sixth of the circumference. The knife, as it is withdrawn, is then brought once more with its point directed towards the centre of the chamber, so as to make a similar square extremity of the incision, to the end at which it was begun.\* Then, as in the excision-operation for artificial pupil, the fine curved iris-forceps is introduced, and the toothed points opened in the anterior chamber (unless the iris have prolapsed, with the flow of aqueous humour, when the corneal wound was completed) widely enough to seize a rather large portion of the iris. This is then drawn fully out, and is first cut through with the iris-scissors vertically on the right side; then, the blades of the scissors being held flat on the surface of the globe, it is divided along its ciliary attachment, close to the opening into the anterior chamber, and, lastly, it is separated altogether by another vertical cut. The operation is then complete. If much bleeding into the anterior chamber occur, the blood must be, if possible, coaxed out in one way or another, before it has formed a clot. The point of the curette between the lips of the wound, or on its posterior lip, may do this; or the blood may be pressed out with the convex back surface of the same instrument, by passing it, wet with tears so as not to abrade the epithelium, from below upwards over the front surface of the cornea; or, by gently pressing back the wire-speculum upon the eye, it may be squeezed out. If there be bleeding, however, some blood will probably be left, and cannot be removed. The eye is tied up with some lint, wet or dry, over it, and a bandage is applied over both eyes.

*Diagnosis of Glaucoma.*—In the diagnosis of a case of glaucoma, much stress must not be laid on the meaning of the word—the sea-green colour in question is often not at all seen in the reflected light from behind the pupil. The chief diagnostic signs are these:—1. *Tension* in excess—varying from the least degree T. 1, to a stony hardness, T. 3. It is appreciated by the two forefingers, used much as in trying elsewhere to discover the existence of deep-seated pus, the patient looking down and gently closing the lids; or the amount of tension may be appreciated by the eye, as well as by the touch, by placing the point of the

\* This method of making preliminary corneal incisions in preference to those made with the thrust of a keratome or the counter-puncturation of Von Gräfe's knife (see Cataract, page 369) has, I am glad to find, been adopted on principle by some of my colleagues since the last edition of this work.

X In doing this I find that, involuntarily, I always close my eyes, by which I suppose the more common my attention on the incision to be then appreciated by the use of the (other) sense of touch.



forefinger on the ciliary margin of the patient's lower lid, and indenting the globe as he looks up. 2. *Pain* in and around the eye, which is often intolerable, generally intermittent. Rarely does a case of painless (non-inflammatory) glaucoma occur. 3. *Halos* are seen around the light. 4. *Presbyopic* symptoms are present. 5. There is *narrowing of the field* of vision. 6. There are *obscurations*. 7. The *appearance of the eye* externally: *a.* Large tortuous vessels are seen to course over the sclerotic, and dip into it in the ciliary region; *b.* The anterior chamber is shallow, the lens, and the iris with it, being, by pressure from behind, thrust forwards in approximation to the back surface of the cornea; *c.* The pupil is large and inactive; *d.* The cornea has more or less lost sensibility, and reflects light from its surface imperfectly; *e.* The lens is perhaps cloudy (not cataractous, not opaque after iridectomy.) 8. *Ophthalmoscopic appearances.* When the fundus can be seen (and it very often can be, though the aqueous and vitreous humours be somewhat obscured, even when the cornea looks steamy and the lens cloudy), the excavation, more or less, of the *entire surface* of the optic nerve-entrance, and tortuosity and congestion and pulsation of the retinal veins (and arteries), which are displaced and compressed against the white margin of the "cup," and some little ecchymoses therefrom, perhaps, are the marked features. These signs are all due to increased intraocular pressure, as is shown directly by the excessive tension (the first diagnostic sign given) in consequence of the contents of the globe being more than is normal.

Glaucomatous is a term applied to symptoms of increased intraocular pressure (tension) in other diseased states of the eye, in which iridectomy is performed with much benefit to the patient: *hardness of the globe* being in any such cases whatever, the indication for the operation. As it is specially important to recognise glaucoma in its first stages, we must not look for the corneal and lenticular changes, or much "cupping" of the optic nerve in all cases of the disease, or the operation will have been deferred long after it should have been done. Glaucoma is a disease of elderly or of old people of impaired health. The earliest symptoms are, to the patient, perhaps, intermittent obscurations, halos, and more or less wandering pain; and, to the Surgeon, increased tension, some congestion, dilated pupil, shallow anterior chamber, and, ophthalmoscopically, some excavation of the optic nerve-entrance and venous pulsation. In the case of an eye blind by old neglected glaucoma, iridectomy will perhaps relieve pain; but probably it should be extirpated.

The benefits of iridectomy, properly performed, and sufficiently early in glaucoma, are patent; and it must be done, when the opportunity offers, even when the time most favourable for its performance is gone by, and even in the chronic cases, in which the results are always least advantageous. Without operation, glaucoma certainly ends in total blindness. It is probably, in the first place, choroiditis, and effusion in the vitreous space. It goes on by producing such structural changes in all the tissues of the globe, that total disorganisation is the result.

PROLAPSE OF THE IRIS.—This means a bulging of the iris through an ulcer which has perforated the coats of the eye, or through a wound in these coats, either made accidentally, or in the course of a surgical operation. It is often caused by the first gush of aqueous humour as it escapes when the perforation is complete, and remains there passively until it is either pushed back into its place with a spatula or curette, or made to return by causing contraction or dilatation of the pupil by instillation of a solution of (atropine or) Calabar bean, one or the other, as the case may seem to need. It is evident that, if the external opening should be in or very near the centre of the cornea, a prolapse of the iris cannot occur; it cannot be very far from the corneal margin, the position in

which most of our internal surgical operations are commenced. If a prolapse is to be returned, *it must be done very soon* after it has occurred, or the iris will probably have become adherent to the margin of the external opening, forming what is called synechia anterior, or, compressed between the edges of the wound, the iris will have at least become strangulated. In iridectomy operations, however, it is an advantage that a prolapse of the iris following the current of the aqueous humour should take place; for then we need not introduce to the anterior chamber the forceps by which it is to be drawn out.

In other cases, prolapse of the iris is caused by pressure of the aqueous or vitreous humour behind it, and is not brought about in any sudden or impulsive manner; it is then discovered as a little bag of a dark colour—whatever may be the natural colour of the iris. If, being recent, we hope to return the prolapsed iris intact, Calabar bean and a strong light may be tried; and the return may be aided, if the prolapsed iris be distended by the aqueous humour, by gently pressing it back with the end of a spatula, by puncturing the most prominent part with a needle and relieving the distension, or by closing the lids and making some pressure upon them and rubbing them gently with the finger. The iris bulging may be already adherent to the margin of the external opening and cannot be returned; yet it may increase by the opening becoming larger or by an increase of pressure from behind, and this we must guard against by artificially contracting or dilating the pupil, as the case may be, by continued pressure of a pad of wool and a bandage, or, if the prominence be much, by puncturing it, or, supposing it to have become firmly adherent, by snipping it off with a pair of small scissors.

In the old operation of extraction of cataract by a semicircular flap, the iris, which is to be left intact, often prolapses, and this is one of the chief difficulties of this operation. It occurs either at the time of the operation, the vitreous humour, after the lens is gone, causing it to bulge forwards between the lips of the wound; or the iris is found, after some days, to be involved in the weak and slowly progressing cicatrisation of the same. In the former case it should be smoothly and gently pressed back into its place with the flat side of the spatula held horizontally, and then, all pressure being taken off the globe, the lids are to be closed and so the lips of the wound kept together. When the prolapse is discovered some days after the operation has been done, of course it cannot be returned; pressure may then be employed, or, if the prolapse be considerable, it may be punctured or incised, or, better still, the prominence, if sufficient, be cut off.

**SYNECHÆ: CORELYSIS.**—*Anterior Synechia*, or adhesion of the iris to the cornea, only takes place when the two have been brought together for a time by evacuation of the aqueous humour, generally by perforating ulcers of the cornea (see Prolapse above, and Iriddesis, p. 355.) *Posterior Synechia*, or adhesion of the iris to the lens, which is very much more common, results from iritis; and these adhesions, once formed, are seldom detached, as in any case they should be if only it be in any way possible: for, if not, an iritis can hardly be said to be *cured*. Posterior synechiæ may be numerous, or the whole round of the pupillary margin may be bound down to the lens—total posterior synechia or exclusion of the pupil: if this be so, no communication exists between the anterior and posterior aqueous chambers, the circle of the iris projects forwards around the central depression in which is the adherent pupil, and presents a very characteristic appearance by oblique illumination. It is important also, for it is an urgent call for an immediate operation: the communication between the two aqueous chambers must be re-established by an iridectomy. If posterior synechiæ be few, or even numerous, the iritic inflammation having subsided, a certain amount of permanent injury, a source of irritation, and a liability to

recurrence of iritis, therefore, at any indefinite time, are left ; but the damage if there should be total posterior synechia, tends always and *at all times, without intermission or hope of abatement*, to aggravate itself, by the *constant* dragging, the great tension that is kept up, by the accumulation of aqueous humour from behind, upon the iris between its greater and lesser circumferences, its ciliary and pupillary borders. Occlusion of the pupil is a very different case : it is when the pupil is filled by a false membrane after an iritic inflammation : the pupil may be, and is, very probably, also excluded, but if it be only occluded, it may not be bound down to the lens at all, and the aqueous humour may pass freely from the posterior into the anterior aqueous chamber through the occluded pupil : in some such cases I have opened out the false membrane and made a central pupil, without at all interfering with the iris. (*Ophthalmic Hospital Reports*, Vol. II., page 311.)

If iris-adhesions be few in number, three or four perhaps, and these be not wide, if the iritis have occurred but once, at least two or three months previously, and the iris seem, otherwise healthy, able and ready to dilate, as much as could be expected, considering the adhesions, under the influence of atropine, and the latter remedy have been fairly tried (a drop of a strong solution placed in the eye three or four times a day for a week) and have failed, I have been in the habit of detaching them with a spatula-hook passed between the iris and the lens (*Op. cit.*, p. 309). There is no fear of wounding the lens. But, now, unless circumstances be altogether favourable, according to the above data, I am afraid of lighting up a fresh iritis and of getting re-adhesions after the detachment has been done. The results of *Corelysis*, as I have called it, are altogether encouraging in these favourable cases : the patient, not old in years or in general health, his iris fully dilated, and able to dilate, but for a few tense adhesions posteriorly by which it is distorted. But, in most cases, the adhesions are either more numerous and extensive, or they have been, just after the iritis, detached by the proper use of atropine : if this have not been and cannot be accomplished, and the adhesions be numerous or extensive, or both, the question of an iridectomy arises. If vision (the pupil) be much obstructed, together with the fact of the adhesions, an iridectomy, by way of artificial pupil, must be done. Without much impairment of vision, on the other hand, if the iritis should become recurrent, an iridectomy, larger and upwards, is required for the purpose of arresting the recurrences (see Iridectomy). If the pupil be somewhat blocked, besides the synechiæ, and there be recurrent iritis, still it is iridectomy. The two reasons for iridectomy coexist, and probably it will be desirable to make a rather large iridectomy down and inwards ; or a large iridectomy may be made in the usual upward direction, and, subsequently a small iridectomy, by way of artificial pupil, in the *opposite* direction.

#### CATARACT.

Until within a very few years, it was considered an easy matter to determine, in any case of cataract, what operation should and would be done. One was a case for extraction (by a large flap, as it is now called), another as certainly would be removed by needle-operation, and a third by linear extraction, as it was called. Now every ophthalmic Surgeon is in search of some improved method which shall diminish the number of his unfavourable results ; and everything is changed for the better, or it may be for the worse. It is rather a bold thing, as far as the profession is concerned, to do an extraction as it is used to be done, making a semicircular section of the cornea, &c. This state of uncertainty makes it also very much more difficult to say what operation is meant by name, or to venture to recommend any particular operation in any case.

FORMS OF CATARACT.—Cataract is most common in old or elderly persons, and in them it is of the kind called *Hard Cataract*. In younger persons, and especially in children, cataracts are comparatively *soft*. The *Senile Cataracts* are generally striated; the streaks being very evident in the commencement of the disease, and less seen as the whole lens becomes opaque: the lenses are generally a little amber-coloured, especially in the nucleus. The other cataracts are comparatively little or very indistinctly striated, and of a milky colour. Striæ in the lens are almost invariably found to radiate from an opaque central spot to the circumference (Fig. 461), or to project towards the centre from various points of the circumference of the lens (Fig. 460). In fact the striæ, according to the direction of the lens-fibres, of which some only have become opaque, always diverge from or converge to the centre of the lens. In hard cataracts the cortical parts, as in the normal lens, are always comparatively soft, sometimes very soft, with a hard nucleus only; but these are cases of secondary degeneration, by which, even the nucleus may at last become dissolved. In rare cases, an indefinite central haze, without any pattern, indicates the beginning of cataract. But there are not unfrequent cases of haziness of the lens, as a senile change, or from intraocular pressure (see "Glaucoma"), which must not be called cataract, for it is sometimes found together with good vision, and the haziness may disappear, or it may never go on to a complete or real opacity of the lens. It is not, in fact, the beginning of cataractous changes. This is an important distinction; and no doubtful case must be said to be one of cataract, unless, by examination with the ophthalmoscope, by the direct or oblique methods of illumination, striæ or some certain opacities be seen in the lens, or such a degree of central haze in the same situation as to obscure the image of the fundus, when, by direct illumination of the ophthalmoscope, a *bright* light is thrown into the eye. If any less definite rule be adopted, it will lead to innumerable misunderstandings and false anticipations. When an eye, in which striæ exist in the lens, the rest of it remaining transparent, is examined by direct illumination, the pupil, of course, having been first of all dilated with atropine, the *mirror* of the ophthalmoscope only being required, the several streaks appear black, in front of the light behind them of the brightly lit-up fundus of the eye (Fig. 460); whereas, when a commencing cataract is examined with a side light, and the ophthalmoscope *lens* only used (oblique illumination), the striæ appear



Fig. 460.—Commencing Cataract: Opaque streaks converging from the margin: the darker striæ are in the anterior parts of the lens.

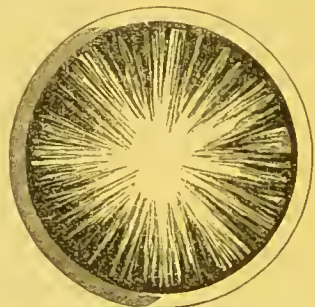

Fig. 461.—Commencing Cataract: Opaque streaks diverging from the centre. The lens-nucleus is altogether obscured.

whitish against the dark pupil; for the light is reflected from the front surface of opaque parts of the still partly transparent lens (Fig. 461). Thus, by these two methods, we have, in doubtful cases, a means of checking our diagnosis. The cases of *hazy* central commencing opacity of the lens, which are to be

called cataract, have been defined already. Of course, in case of a patternless non-striated opacity of the lens, far advanced, the *whole* lens so evenly opaque that no part of it allows an inspection of the fundus, there need be no question of the existence of cataract. That the opacity is not in the cornea, or in any part behind the lens, is found at once by observing the apparent change in the relative position of the parts, when, in a good light (oblique illumination), the observer moves his head from side to side, whilst the patient keeps his eyes fixed on some other object. That it is no opacity in the pupil, is known by the use of atropine, which must of course always be used beforehand for the diagnosis of cataract, in doubtful cases, and which will not regularly dilate the pupil if this be not free. Of course there may be obstructed pupil and cataract behind it; but then we cannot certainly make out the latter. Or, if there have been iritic effusion and adhesions now freed, there will be evidence of old iritis. Or, if the opacity be in the vitreous space, it will be evidently so far behind the level of the pupil as to show its situation by oblique illumination.

Besides the idiopathic, there may be, at any time of life, *Traumatic Cataract*. Any wound of the lens, unless it be a slight clean cut or puncture, and not very deep, is followed by opacity of the whole lens. The surgical treatment of senile or hard cataract, of soft cataract, and of traumatic cases, is very unlike in many respects. In the latter only is there urgent need of any operation being done. Wounds of the eye (and lens), as of other parts, when they have occurred, are generally found to have been in young persons, or at least not in old people. Hence traumatic cataracts generally resemble the more the soft cataracts, so called, in being soft and whitish. In older persons, when the opacity follows a wound of the lens, it will be found to have a hard nucleus, if it be not altogether hard. The wounded lens becomes opaque, swells up considerably, except the nucleus in old people, and in young people very rapidly, by the admission of the aqueous humour; and herein usually lies the urgency of the call for surgical interference. The swelling of the whole lens and the gaping wound of the lens-capsule, by which an irregular protrusion of swollen lens-matter takes place, if the lens be not wholly swollen, press upon and rub against the iris and ciliary processes in their movements, and set up iritis and deeper-seated inflammation, which will not, of course, subside until the exciting cause is removed. Those opacities of lens, also, which follow blows on the eye, or severer blows on the head (without any external wound of the eye), by which the lens is dislocated (or *partly* separated from its natural connexions, so that it, and consequently the iris, are somewhat tremulous), must be included among the traumatic cataracts. It is in traumatic cases, accidental or surgical, and in these only, of cataract, that no delay is permitted if an operation be required: the curette, the suction-curette, or the spoon must be employed at once, and as much of the cataractous lens matter removed as can be without much interference.

Cataracts affecting, for the most part, only the cortical fibres of the lens, have been called *Capsular*. *Anterior Capsular Cataract* shows of course the shape of the convex surface as it is seen in front and just behind the pupil. In *Posterior Capsular Cataract*, there commencing, the striæ appear concave and rather yellow, not white, because they are seen through the thickness of a lens which, by age, is yellowish, as are all old lenses, cataractous or not; and some of them, without being cataractous, have yet a slight haze in them, nevertheless not a commencement of cataract. Secondary cataracts, consequent upon some disease of the deeper parts of the eye, are seen commencing in the centre of the posterior surface of the lens. Capsular cataracts are only commencing cataracts, where the opacity first appears in the cortical layers.

GENERAL REMARKS ON OPERATION.—If cataract begin as a stellate central patch in the lens (Fig. 461), of course vision is at once much interfered with, and is probably benefited by the use of atropine from time to time; whereas, in both these respects the reverse is true, if the striæ project only towards the centre from the circumference of the lens (Fig. 460). In any case, even the most complete, of cataract, it must be remembered that, though the fundus of the eye cannot be seen by the Surgeon, the patient can always, if the case be uncomplicated, see a bright light very well, the other eye being covered, and can at once equally tell the absence of it when the hand is before it. The “field of vision,” also, within which the patient can see the light, is not reduced in size. The patient has not the hopeless look of blindness of an amaurotic patient; he seems to look for the light and to enjoy even such vision, of light only, as he has left to him. So it is also in any case of non-nervous blindness, in leucoma, &c. Also, in the diagnosis of a case of cataract to be operated on, one expects to find a pupil ready to dilate well or to contract, a good-sized anterior chamber,—in fact, an apparently healthy eye but for the cataract; no increase or decrease of tension of the globe; no history of former pain, and so on. Arcus senilis is no reasonable objection to operation. Cataract, unless it be traumatic, in which case the history is our guide, and the lens becomes cloudy in a few hours or days, is, of course, comparatively of slow formation, very slow indeed in the senile forms; but blindness or partial blindness in one eye from cataract, or indeed from any other cause, without pain or redness, is not unfrequently discovered suddenly and by chance, by the patient accidentally closing the other eye, with which he has been seeing, so that the history given us may require a complete mental refutation, lest we be led to fear any unfavourable complication not existing in the case.

An *incompletely opaque lens* must not be operated on for its extraction if the operation can be deferred or avoided: but it cannot be in some cases of so-called congenital cataract, in which the lens opacity is central and so large as to need the loss of the whole lens (see, on the other hand, Irididosis), or in cases in which very slowly progressing senile cataract has produced so considerable a *central* opacity in the lens of *both* eyes of a patient, as, without rendering the lens of either completely cataractous, to have made the patient practically blind. Then either one may use the needle once or twice beforehand, and, the whole lens having consequently become opaque, it may be regularly extracted; or the risk and danger of extracting immature cataracts must be borne. (I have had no practical experience of the extraction of cataract *in its capsule*.) For portions of transparent cortical lens-matter are sticky, and adhere to the portions of lens-capsule remaining in the eye after an extraction-operation, and to other parts; besides, if they were not thus difficult to remove, and did not require much interference for their removal, they are transparent at the time, and so cannot be seen to be removed. The preliminary needle-operations are not very satisfactory in practice: for the central, very slowly progressing cataracts, equal in each eye, of old people, needle-operations are in themselves rather dangerous (see p. 374), and they take much time whilst one is striving to hasten the end; for two needle-operations or a following extraction-operation cannot be done at short intervals safely, and a senile cataract very slowly becomes opaque, even when the capsule is opened, and an iritis is never improbable. The congenital forms occur in younger, perhaps very young patients; and, very often, a needle-operation having been done in order to the maturation for extraction of one of these cataracts, it will be found better to complete the operation by repeated use of the needle only.

If one eye be cataractous, the other still retaining more or less useful vision,

the cataract may be operated on, if complete and otherwise fit for operation : but it cannot be right to urge the operation which may well be deferred, and need not now be done. If the seeing eye show a commencing cataract, a patient will, not unfrequently, desire the removal of the complete cataract, so as to have prospectively the use of the then practically blind eye when the other fails him. If the seeing eye do not show any commencement of cataract in it, the history and examination of the case require more particular attention in order to its diagnosis—that it be not traumatic, or, if it be, at least that vision, independently of the cataract, be good. Perhaps operation may be advisable. I have sometimes, for cosmetic reasons, extracted a cataract in a blind (amaurotic) but otherwise, externally, healthy-looking eye. Even with the densest or darkest coloured cataract the patient has, in an uncomplicated case, a good perception of light and field of vision. If there should be cataracts in both eyes equally advanced, both fit for extraction, I prefer to do one first and the other a few months afterwards ; but I would not refuse to extract both at once if good and special reasons were given for my doing so. I have known both eyes to be lost after a double extraction.

The object of the operations for cataract is the removal of the opaque lens from the axis of vision. Subsequently to the operation, instead of the natural lens, an equivalent glass lens is placed *before* the eye—for near objects about  $2\frac{1}{2}$ , and for distant objects about  $3\frac{1}{2}$  inches focus. The points to be observed are, either the getting rid of the cataract very gradually by natural process of absorption, when, in young persons, the capsule being lacerated, and the lens wounded, by operation from time to time, this can be accomplished ; or, otherwise, the more rapid removal of the cataract, the opaque lens-matter, by laceration first, and then evacuating by as small an opening as possible in the cornea ; or, thirdly, by extraction of the whole at once by a sufficiently large opening. After the operation, we have merely, as a general idea, to let nothing, by any movements brought about directly or indirectly, hinder the healing of the external wound, or interrupt the complete rest and seclusion necessary for the recovery, without inflammation, of the various internal structures that have been disturbed.

Before any cataract-operation, belladonna or atropine drops may be well used, although, if the aqueous humour be let out, the iris will contract at once. At any rate the application keeps the pupil dilated in the beginning of the operation, so that one can see well the cataract ; it shows also that the pupil *will* dilate, and how much it will dilate, and it inclines the pupil to dilatation during the operation and subsequently. I do not think that the iris is ever brought any more in the way of the cutting edge of the instrument used in opening the cornea, by its expansion, as is asserted.

In any operation for cataract, care must be taken not to urge the vitreous humour to escape, nor inadvertently to rupture the posterior lens-capsule, nor to bruise the iris or cornea ; and not to leave any lens-matter or clot of blood, not only in the former situation of the lens, if, without much interference, they can be thence removed, but also in the lips of the corneal opening, where they will interfere with the healing process.

Formerly, when the only method of extraction of senile cataract was by a flap involving a section of one half the circumference of the cornea, very many precautionary rules were to be enforced that are now of little or no importance. Then cataracts were only extracted in the spring time—the time we now only consider to be best. Then, if a patient were intractable, the prognosis was very unfavourable, if the operation were done at all. Now, the administration of chloroform during the operation, and perhaps of chloral subsequently, have

almost set aside this objection. The great extent of the surgical wound in the cornea, then deemed indispensable, was naturally an evil prognostication if the patient were feeble, lest the section should never heal, or the cornea die of malnutrition; or, if the patient had an habitual cough, it was ominous of vitreous escape through so large an opening, or of prolapse of the iris at least, in the same way. Iris-adhesions, always unfavourable, when no iridectomy was done, were a fatal objection to an extraction. Our patients now-a-days have great advantages at least in the improved methods of extraction. But no result of any surgical operation is so beautiful as a *successful* extraction by the old semicircular flap; and, all things being favourable, the patient completely anaesthetised, it may still be done in some few cases.

Hard or senile cataracts are extracted wholly and at once by one of the three following methods.

EXTRACTION BY FLAP-OPERATION.—The old operation of extraction by a semi-circular flap is thus done. The patient is lying on his back on a high couch with his feet to the window; the Surgeon standing behind him, having cautioned the patient against any irregular movement on his part, puts his forefinger against the lower edge of the patient's upper lid, using his left hand for the right eye of the patient, and *vice versa*, raises it, and holds it securely against the upper margin of the orbit. The middle finger is put on the surface of the globe, on the nasal side, to keep it from rolling inwards. An assistant has charge of the lower lid, which he depresses and holds securely against the edge of the orbit without any pressure on the globe itself. The Surgeon, with the extraction-knife, held like a pen in his other hand, again cautions the patient, tells him to look towards his feet, and, resting the hand with the fourth finger on his cheek, enters the point of the triangular knife (Sichel's) at the outer side of the cornea, near its margin; then, not allowing the eye to be rolled in, he thrusts the knife rather quickly across the anterior chamber in front of the iris, and penetrates, from within, the cornea at the inner side, making the counter-puncture just opposite to and symmetrical with the first; so that the upper half of the cornea is in front of the knife or before its cutting edge. The knife is now only thrust onwards as far as it can be, until the flap is completed: but this, very probably, cannot be done but in drawing the knife back again a little, or by little to-and-fro movements. Until the section is nearly completed, and the knife has passed in front of the whole iris, it must not be at all retracted; or the aqueous humour is allowed to escape, and the iris falls in front of the cutting edge. The lids are now freed, and the patient told to keep them gently shut. After a short rest the lids are held open, but they need not be again so firmly fixed as before; the patient is then told again to look down, the convex back of the pricker, held horizontally, is inserted between the edges of the corneal wound, carried down to the pupillary area, and turned with its point against the capsule of the lens. Then, by a few light scratches, this is freely lacerated and the instrument withdrawn, with its back turned upwards, so that its point may not be caught in the iris or cornea. The eye is again closed for a minute, and when again opened, it is by the operator only, who raises the upper lid as before, but without much pressure against the edge of the orbit, and then he places the convex back of the curette horizontally on the skin of the lower lid near its margin. With this he makes intermittent light pressure on the globe just below the ciliary region, and synchronous counter-pressure with the point of the forefinger, which is holding the upper lid at its margin against the ciliary region just above the corneal wound. This requires much tact and attention. If the globe be compressed too far back, the lens will escape violently, and not improbably with some of the vitreous humour. If it be compressed too far in



front, the lens may be dislocated, but not out of the eye ; it may fall back into the vitreous space and be lost. If all go well, the upper edge of the lens is seen to come forwards through the pupil which it dilates, and then rides over it and presents itself in the corneal wound. The pressure should be kept up or increased, until little by little the lens has advanced so far that at least more than half is without the wound. Then, the pressure exerted being little and equal, the lens, if it remain in the wound, may be rolled out sideways with the tip of the middle finger of the hand which steadies the upper lid. This is better than increasing the pressure up to the final evacuation of the lens, as vitreous humour may follow it, and better than omitting altogether the pressure exerted, or much of the softer cortical parts of the lens are likely to be detached and left in the lips of the wound and in the anterior chamber. Any such are in the next place removed with the curette, if it can be done without much interference. If the iris be now inclined to prolapse, it may be pressed gently back with the small spatula, made for the purpose, held horizontally. The instruments, knife, pricker, &c., are all held horizontally ; so that if the eye, ill controlled by the patient or Surgeon, should, in any stage, roll upwards, as it has a tendency to do, the instrument in hand may not pass downwards into the deeper parts of the eye, but be forced out of it by this movement. The iris now being in position, the pupil clear, and nothing being left between the edges of the corneal wound or within the palpebral aperture, the lids are gently closed, a smooth oblong piece of linen rag, with a slit in it for the nose, is placed over both eyes, then a little wool is put in the orbits over the rag, and a bandage over it round the head. The patient is kept in bed for a day or two, and fed with spoon meat. He may then get up and walk about the room a little.

EXTRACTION WITH A TRACTION-INSTRUMENT.—In this operation chloroform is given, and a wire speculum to keep open the lids, and forceps to hold the eye, are used. The Surgeon either thrusts in at the upper part of the scleroticocorneal junction a lance-shaped knife in his right hand, or, what is preferable, the point of a Sichel's extraction-knife, at the right extremity of the incision which he intends to make in this part of the eye, and, holding it almost vertically, he cuts on as far as he intends, perhaps one-fourth of the circumference, to the left. He then makes a considerable iridectomy, larger than for artificial pupil, and not so large as in a case of glaucoma. Then with the pricker he lacerates the lens-capsule. He then passes the end of the traction-instrument (Critchett's spoon) between the lips of the wound, vertically, to the upper edge of the lens and within the capsule, rather posteriorly ; and, remembering anatomically the curve of the hinder capsule, he passes it along the curve just behind the lens itself. He then tilts forwards the end of the spoon, and, watching that the lens is coming with it, he begins to withdraw the instrument and the lens together. If the spoon will not go on between the lens and its capsule, it may be introduced perhaps a little sideways ; and as soon as it has begun to pass between the two, it may be passed all the way without difficulty. If the lens is being pushed before the point of the spoon, instead of the latter passing behind it, it will be seen, the front surface of the lens being purposely watched, to be passing downwards ; and we must try some other way, sideways, as above directed, or further backwards, and not of course push on the instrument so as to displace the whole lens downwards. The piece of iris excised must be so large that what is left does not become compressed between the spoon and the cornea, in the removal of the lens ; and the corneal opening must be so large that not much dragging is required. The main body of the cataractous lens being extracted, the concavity of the posterior capsule, in which it rested, is pressed

forwards by the vitreous body behind it, and so, if any fragments of opaque lens be on it, they are presented forwards in the pupil, and a spoon may be employed once or twice for their removal. No blood-clot, nor any lens-matter, nor, of course, the edges of the iridectomised iris, must be left in the corneal wound.

**EXTRACTION BY VON GRÄFE'S METHOD.**—Since the last edition of this work, four years ago, this operation has grown immensely in favour with ophthalmic Surgeons, and almost all senile cataracts are now extracted in this way ; or, at least, this operation is the grand foundation on which individual operators have built their modifications in details according to their own inclinations. First of all, we may observe that the idea seems to be based on two principal facts : 1st. That, to extract a cataract, it is not necessary to make so large an opening as a half section of the cornea, as in the old flap-operation—which, indeed, became clear to us some years ago, when the traction-instruments were invented ; and 2nd. That it is equally unnecessary as a rule, even with the smaller opening, and very undesirable on all accounts if its use can be avoided, to introduce any traction-instrument within the eye, as is done in the operation last described. (If Von Gräfe used any such aid in any case, it was a small blunt hook instead of a spoon.) The incision is made with a knife like a sharp-pointed tenotomy-knife, by puncture and counter-puncture, of perhaps one-fourth of the circle of the sclerotic-corneal junction. Attached to the corneal flap is left a flap of conjunctiva to cover the incision. An iridectomy is made, and, of course, the lens-capsule is lacerated in the usual manner. To evacuate the lens, the back of the curette is pressed against the sclerotic margin of the incision, and the necessary counter-pressure below is made with the fixing forceps. The cortical lens-matter generally remains to be removed, after the nucleus has come out or has been removed by the hook placed under and around it. Von Gräfe says that the advantages are the following :—1st, the incision is linear ; in consequence of which the co-aptation of the edges of the wound is more perfect than is the case after a flap incision, and there is less risk of gaping of the wound, permitting loss of vitreous humour after the performance of the operation : 2nd, it is peripheral, passing chiefly through a vascular texture, in which the healing process occurs more rapidly than in a non-vascular tissue : 3rd, the incision may be viewed as subconjunctival, being covered by a flap of conjunctiva : 4th, a portion of iris is removed, and thus no prolapse of iris can occur, and the tendency to iritic inflammation is diminished : 5th, in most cases no instrument is introduced to assist the evolution of the lens, and, when such is necessary, a hook merely is employed ; and 6th, the after-treatment is of short duration.

Now probably no extraction by Von Gräfe's method is ever done in all its stages, exactly as Von Gräfe used to do it, and no operator is free from all prejudice in favour of his own particular modifications, which indeed to him only, it may be, are advantages in operating ; but some few practical remarks as to my own experience of this now established method of performing the most important of the capital operations in eye surgery may be useful. The pupil is under the influence of atropine. The anæsthetic preferred may be fearlessly given ; and, the patient being well under its influence, a spring speculum (Fig. 453, *a*) is introduced between the lids, and the eye itself steadied by grasping a considerable fold of conjunctiva at some distance below the lower margin of the cornea, with the toothed forceps (Fig. 453, *b*). For either eye to be operated on, I stand, as usual, behind the head of the patient lying on the couch, and hold the forceps generally in my left hand, because, in my way of making the corneal section, the knife for either eye may be as conveniently held in the right hand. I prefer a Sichel's knife, as in

iridectomy (p. 358), in the present operation; not that there is anything to be feared in wounding the lens, or that it cuts better than Von Gräfe's, but because with it a section of the cornea can be made less obliquely in all its extent than by puncture and counter-puncture, which, in iridectomy for glaucoma, is also an advantage; and especially because, *with so small a section of the cornea as is now made, the counter-puncture extremity of the section, when a counter-puncture is effected, makes so small an opening in the anterior chamber as compared with its size externally, and this is a deception, for of course its least dimensions are only practically available in the evacuation of a lens.* The point of the knife being directed towards the centre of the pupil, the cornea is transfixed at its upper margin at the right hand extremity of the intended incision; the point of the knife is then carried on between the cornea and iris along the upper circumference of the anterior chamber. No counter-puncture is made, but the knife is quickly brought into a more vertical position, and with a firm hand, and quickly, by little to-and-fro movements, the section is continued as far as need be to the left extremity of the intended opening. That this extremity may be square like the other, and not at all oblique, the knife should be either drawn out at the end of the section, held quite vertically; or, the knife being held horizontally, the edge is brought upwards and forwards, and its point is made so to cut its way out suddenly at one stroke. The corneal opening should be as large as one-third of the circumference of the cornea; it had much better be unnecessarily large, than a little too small in any case; it is easily extended at either end, if it should seem to be necessary, by re-introduction of the point of the knife into the anterior chamber, and cutting right or left. No conjunctival flap is left to cover the wound: it is doubtful if, when it has been left, the corneal wound heals any the better. A considerable iridectomy is as usual made (p. 358), and the lens-capsule opened (p. 366). To evacuate the lens, the back of the curette, held horizontally, is now pressed on the globe between the lower margin of the cornea and the point below it, at which the globe is held with the fixing forceps. By moderate pressure backwards, gradually increasing, and by a succession of little sliding movements from below upwards, never reaching the edge of the cornea, the upper margin of the lens will begin to protrude at the corneal opening, and dilate it: as soon as it is certainly advancing out of the eye, the sliding movements must be discontinued, and the simple, very gradually increasing backward, and upward pressure alone is to be kept up on the eye or the lens; its largest part not having passed the opening, may recede as well as advance alternately with each up and down movement of the curette, and the extraction might never be completed. This steady backward pressure is to be kept up patiently until the largest part of the lens is certainly quite outside the corneal opening, when the whole body of the lens will probably fall aside out of the way, or it may be pushed aside, only not with the curette, for the pressure must not be altogether intermitted. At least we are no more concerned about it, and have only now to care for the complete removal of all the softer cortical lens-matter left behind in the anterior chamber. The curette is continuously pressing on the lower front part of the globe, and now again the sliding movements upwards may be recommenced, still not reaching forwards beyond the lower margin of the cornea; by this the vitreous body advances still more, and the lower part of the iris and cornea are brought into contact with it first, and soon, the pressure and upwards sliding movements being continued, the lower margin of the pupil is seen to be quite clear and black. The curette may now be slid a little up on to the lower part of the cornea; the opaque soft lens-matter will then rise higher, and so gradually, as it is seen to advance, and the clear pupillary space to

*or four fifths*

*that.*

*only opposite to the centre of the corneal section & that, by chance, the section has been made not directly by in the uppermost part of the circumference of the cornea, as it might theoretically have been, but a little on the side, both the section is upwards, & a little upwards or not upwards, then the pressure of the curette downwards & opposite makes below & to one or other side of the case being.*

become larger and larger, the curette pursues it until it is just all outside the corneal opening. At this stage, of course, the slightest continuance of pressure would lead to an escape of vitreous humour. If the curette be at any time slid upwards too soon, so as to get in advance of some of the soft lens-matter, the tendency is to push it back from the corneal outlet, and it will probably never be made to escape, or vitreous humour will be lost. No fragments of lens-matter must be left in the corneal wound or between the lids. A drop of atropine may be placed between the lids. A piece of fine linen (about  $6 \times 3$  inches), is placed over *both* eyes, a little pad of fine wool is placed in each orbital space, and over this is fitted a Liebreich's bandage of elastic knitted cotton, and tied comfortably tight.

Sichel's moderately pointed knife cuts through the cornea better than the very obtuse keratome, or the very acute Von Gräfe's extraction-knife; and in the way it is recommended to be used, the inner and outer openings of the cornea may be made of the same size, square at both extremities, less obliquely through the coats, and the pupillary area is never transgressed. The incision may be less easily done, and less rapidly than is a single movement straight forward with a cutting instrument; but, for the curved incision, a previous determination of the line to be followed and a firm free hand only are needed.

Escape of the vitreous humour is the most important mishap in a cataract extraction operation that is likely to occur. It is not that the loss of any small portion of vitreous humour is in itself very prejudicial, but it is not often that a very small portion only does escape: if a little escape, it is probably followed by more; and the quantity is hardly recognised at the time. If vitreous humour be lost in the operation, it influences the ultimate result unfavourably; the eye is so much the less safe as an organ of vision hereafter, though the proximate result of the operation is successful. In the serous fluid occupying the place of the aqueous chambers and of the lens and the vitreous humour that is lost, the iris falls back out of its place, leaving a very deep anterior chamber, as it were, and has also probably got adhesions posteriorly to some new false membranes. And all synechiæ are, as I have said, in any case, incompatible with a prospect of safety for the future result. But if vitreous humour escape in any cataract operation *before* the lens, or that portion of the cataract which it was intended to evacuate by the operation, the operation is seriously marred; for if then the lens-matter be removed—and, the vitreous body having got precedence, it very likely cannot be,—more and more of the vitreous humour is allowed to escape by necessity. Even if the major part of the lens be after all removed, the prolapsed vitreous body will retain some considerable fragments and press them aside against the iris and ciliary body, and so very likely mechanically set up inflammation. The Surgeon is bound to be alert in detecting the least tendency to or beginning of prolapse of the vitreous body: the opaque lens-matter, instead of advancing, perhaps recedes a little, and soon a small transparent bead appears in the corneal opening. This opening very likely is too small, and needs enlarging; but after this, when the vitreous humour has shown itself once in the wound, still it would be dangerous to attempt the evacuation of the cataract by pressure; a sharp hook for a hard cataract, or a spoon or the suction-curette for soft lens-matter, may be used. Sometimes vitreous humour will escape at the close of the operation, after the lens has been removed; this is in so much less serious; but at all events, if vitreous humour have escaped before the lids are closed and bandaged, the escaping vitreous body should be divided across close to the corneal opening with a pair of scissors; then the wire speculum is raised a little from off the surface of the globe to remove its weight, and to prevent the action of the orbicularis upon it; and then, this

muscle being at the time tolerably passive, the speculum is removed and the eye quietly closed. In the old semicircular flap-extraction operation, vitreous humour was, perhaps, more frequently lost than it is in Von Gräfe's operation; but then, in the latter operation, it is more likely to anticipate the evacuation of the lens.

If the lens, as a whole, or the greater part of it, have fallen down into the vitreous chamber, the attempt is to be made to transfix it with a long needle or sharp hook, and remove it; but, lost to sight—and the ophthalmoscope cannot, in this stage of the proceedings, be employed—it can seldom be reached. Sometimes after a blow, a lens, perhaps already cataractous, becomes separated from its attachments, and, in its capsule, dislocated into the anterior chamber or the vitreous space. In the former situation especially it must be removed at once (because of the mechanical irritation and consequent inflammation of iris and ciliary processes to be anticipated), by a sufficiently large opening in the cornea, made with the point of a cataract-knife—care being taken meanwhile not to press the lens back again through the pupil: if this be avoided, it will in all probability readily enough escape when the incision is completed. I have seen a lens half-dislocated through the pupil, and held by the sphincter iridis. The iritis set up in this case was, of course, very acute. A lens, dislocated into the vitreous space, if quite separated and fallen to the bottom of this space, would be probably visible with the ophthalmoscope even although it were transparent, and had not yet become cataractous. It must be brought forward into the anterior chamber and removed by use of a long needle or a sharp hook, introduced through the sclerotic or in any way most convenient to secure it, if it can be done; but it is very difficult to do this, especially if the lens be still transparent. If the blow have burst the globe, the lens will be found in some cases beneath the conjunctiva, external to the globe. The rupture of the globe is probably in or just behind the ciliary region; and the lens is lying beyond it, further from the cornea. It is seen as a rounded semi-transparent prominence, probably *under the upper lid and far back*, and it is easily removed by opening the conjunctiva underneath which it is lying. Sometimes a lens or cataract is half-dislocated into the vitreous chamber, that is to say, it is held still partly by the suspensory ligament, as by a hinge, and, fixed here, it can move to and fro; it also, of course, must be at once removed. Indeed, a lens, cataractous or not, dislocated, or half-dislocated in any direction, is to be removed—if it can be done; for the lens, if transparent, is not in position to be of use, and beside this, in all probability it must soon become opaque.

**NEEDLE-OPERATION.**—This is the method to be preferred for *soft* cataract at any age, so that we have only to determine which is a soft cataract. It is not often found but as “congenital” cataract, or in traumatic cases in young persons. Diabetic cataracts are soft. If a middle-aged or elderly person have soft cataract, it is as in infants and young persons bluish-white, rather uniform in colour; it has no hard nucleus; and, especially, it is not at all amber-coloured. If, in any cataract case, a needle-operation be necessary, it should be done without much delay. The earlier in life, and the sooner after the commencement of the cataract, the more quickly it will be absorbed afterwards. Infants, unless at the time very young or sickly, should be operated on; or their eyes, when they begin to observe objects, get wandering oscillatory movements as a confirmed habit in after-life; and infants particularly well bear the risks of swollen lenses. Though the lenses of young persons, and still more of children swell up much more, and more rapidly than do those of adults, or still more of old people, when their capsules are lacerated accidentally or by surgical operation, the iris and ciliary processes in them seem very little inclined to

take on inflammatory action by the pressure and mechanical irritation of the, in these cases very soft, swollen lens-matter. The immediate result of the use of the needle in this operation is, that the cataractous lens becomes very much increased in bulk by the admission of the aqueous humour within its capsule.

*Operation.*—The needles used should be very fine, and should not let the aqueous humour escape beside them. The pupil is to be dilated with atropine, which must be constantly employed in these cases during all the surgical treatment. An anæsthetic is sometimes necessary. A stop-speculum is inserted between the lids, to keep them apart; and a little fold of conjunctiva and subconjunctival tissues is to be seized with the toothed forceps just below the cornea, or opposite to the point at which the needle is to be introduced, as may be most convenient, to steady the eye. The needle, held in the other hand, is made to enter the anterior chamber through the cornea, at some part near the margin, wherever it may seem best, probably at the upper and outer part; it must not be passed very obliquely through the coats of the cornea, or in its use they will be much twisted. The point of the needle, having passed the pupillary margin, is then carried on down to the centre of the anterior surface of the lens, which is nearer to the cornea, according to the youth of the patient, and made to enter its substance a little way, and the capsule is torn open by moving the needle-point in various directions to and fro. If the operation be performed for the first time in a very young patient, the lens is so soft that it is very readily broken up by the to-and-fro movements, and by rotation of the needle (drilling), but it soon afterwards swells up very much, and therefore but little should be done. If the needle be passed far into the substance of the lens towards the nucleus, it will, unless the patient be very young, become fixed in the denser substance, and the lens will move about as a whole on the needle, and may become dislocated. If the patient be older, or have been before operated on, one needle will not, perhaps, freely lacerate the tough anterior capsule, and two may be required. The fixing forceps must then be entrusted to an assistant; or, one needle being entered some distance in the anterior chamber, it may be used, the patient being then quiet, for an instant, as a fixing point, holding the eye forwards, until the needle in the other hand has been also entered, and then the eye is perfectly under command. If one needle only be required to be used, it is better to use neither speculum nor forceps, but the fingers of the other hand (Fig. 455) instead of both, unless the eye be small and deep in the orbit. If two needles are to be used, the speculum must be employed, and then, choosing an opportunity when the eye is still, one needle, and then quickly that in the other hand, is introduced; and the operation is completed with the two needles, opening out the lens, whilst at the same time they keep the eye steady.

The needle-operation is always the best for infantile cataract. So, in childhood, if one of these so-called congenital cataracts have been left so long for operation, it should be broken up with the needle for its ultimate gradual removal by the natural process of absorption. Children and young adults hardly ever have any other kind of cataract than the congenital, unless it be the result of some wound or mechanical injury of the lens: then also, if the lens have become opaque, unless already the lens-capsule be sufficiently lacerated, the needle must be employed at once, and again and again whenever it may seem to be necessary to expedite and complete the process of removal, after a longer or shorter time, according to the rapidity with which the absorption proceeds; and this will be more or less, in inverse proportion to the age of the patient. Though the anterior chamber is so small and the iris so close

upon the lens, in infancy, still it seems that nothing is to be feared. In no juvenile cataract will it ever be necessary to make a large opening and remove the lens as a whole.

If the lens, wounded either accidentally, or by the surgical operation, swell much, or, whatever swelling occurs, should there be any symptoms of inflammation of the iris and ciliary processes, more at least than a very slight redness in the ciliary region and no marked tension, which may be disregarded, (and this is more likely the older the patient may be,) the process of absorption is arrested; the lens-matter, or some of it, must for both reasons be removed at once by use of the broad needle and suction-curette, and if among the diffluent lens-matter and aqueous humour be found a solid nuclear portion of the lens remaining, the corneal opening should be enlarged with a knife for its removal with a scoop, if without one it will not escape. Of course, unless it follow an accidental wound, the lens should not be so much exposed by so extensive a laceration of its capsule as to admit of so much swelling that inflammation follows; but this cannot always be calculated beforehand. In *first* operating in any case on an eye by the needle-operation, unless, perhaps, in infants and very young children, it is well not to make more than a small opening in the lens-capsule, for fear of this mechanical irritation and after inflammation; also, I would not extensively at first break up the lens within this opening, or the consequent swelling may open out the whole lens, though the opening made in the capsule, by the needle, was not large. Within a week, even in the older patients, in any case, I think, the greatest amount of swelling consequent on needle-operation will be reached. After that, so long as the bulging lens-matter shows in the wound it may be left—the pupil being merely kept dilated constantly with atropine drops or belladonna lotion, whilst absorption is going on.

In a few weeks, more or less, the lens-matter, which was bulging, no longer protrudes; the surface is perhaps rather flattened, and the situation of the opening made in the lens-capsule is somewhat excavated. The needle then should be used again; and at the second or at least the third time of using it, after sufficient intervals, there is no fear of the remaining lens-matter swelling enough to bring about any inflammation, and it is much more unlikely now that a fragment of lens should be detached and so set up inflammation. Hence the needle may be used in the latter operations more and more freely each time. And the needle must be employed whenever the bulging out lens-matter no longer protrudes, and the wound in the lens-capsule seems to be a little excavated; for, if the repetition be long deferred, the lens-capsule in front may become so tough that it can never be thoroughly broken up, and it will be drawn in at the edges of the surgical wound, enclosing some portions of white opaque lens-matter which, if not in the centre so as to obstruct vision, will show when the pupil is large, and are a defect, in appearance, in the good result to be expected from timely interference. If the capsule be toughened, the lens will perhaps move about on the end of the needle as it is moved about, and the lens-capsule is no more torn open. A second needle must then be introduced from the opposite side of the cornea, and then with it the lens may be held and steadied while the needle in the other hand tears open in various directions the capsule, and breaks up the lens-substance freely; or, if it be very tough, the two needles, introduced from each side of the cornea, and meeting at the same aperture in the lens-capsule, may have their points separated, so as to make a large rent in it. The posterior capsule is throughout to be carefully preserved from any accidental wound. If it should be wounded, whilst the lens is still bulky and softened, and it let the vitreous body come

forward and protrude in the midst of the lens-matter, the vitreous body pushes aside the fragments of broken up lens against the iris and ciliary processes, and mechanically sets up inflammation, which commonly ends badly. It is very difficult—if not impossible—to remove such fragments by the curette or the syringe, without injuring the vitreous body, which lies in the way; it will, however, be better to lose some vitreous humour than to leave much lens-matter pressing upon the iris, &c., if such a mishap should occur, and the fragments *can* be removed. In the *final* stage, however, of “solution” or keratomyxis (as the needle-operation has been called), very little of the lens being left, the carefully preserved *posterior* lens-capsule has not unfrequently to be purposely torn open, and a rent, through which the vitreous body protrudes, to be made; for small opaque fragments often remain upon this capsule, after most of the lens-matter has been removed little by little; or delicate grey webs and streaks and puckerings appear in or upon it, visible, perhaps, only by use of the oblique illumination, and yet interfering very much with good vision. There are now no fragments of lens that can be displaced and excite inflammation.

In old people, or even in adults, a needle-operation is a very tedious process. The lens-matter, though swollen, has irregular hard margins, and will very likely set up inflammation of the iris and ciliary processes, &c. A detached fragment of the hard senile cataract left after an extraction will be very likely to do the same; and elderly people, in any inflammation of the eye, are always more likely from their age to get a glaucomatous complication of the disease. But if a young adult have one useful eye, a cataract in the other may be got rid of by repeated use of the needle, doing each time very little with it; and the process, tedious as it is, is safe from the greater risks of extraction; and the inconvenience of the delay, in such a case, will not be felt. If in this process of solution there should in any case appear to be increased tension (T. 1.) even though the pupil be fully dilated (atropine of course being used) and there be no ciliary redness, the swollen lens-matter must be at once evacuated, and afterwards an iridectomy upwards done at the same time.

SUCTION-OPERATION.—Fluid cataracts are sometimes, but not often, found; the whole contents of the lens-capsule being evacuated into the anterior chamber when the capsule is torn open with a needle. They occur, perhaps, in young adults for whom we should use the needle. They look like soft cataracts; and they can hardly or unfrequently be distinguished from ordinary soft cataracts, besides that from their rarity they are not expected. They appear of an uniform colour. Somewhat like them surgically are the cataracts of diabetic patients, though these latter are not fluid, only very soft; so that, after the needle has been used, although the patient be middle aged, the whole of the lens is mixed up in the aqueous humour, and can be, and indeed must be, removed lorthwith. In this I am speaking of my recent experience, in which I have had a succession of cases of diabetic cataract, all alike, and all successfully treated by suction, at one operation, as described below. I do not say that all diabetic cataracts must be like those to which I refer: they were of a bluish milky colour, very large, apparently pressing forwards the iris, with some broad, convergent, indistinctly glistening striæ anteriorly, rather lighter in colour than the body of the lens itself. The syringe is also available in the cases of wounds of the lens in children or young adults, in which, soon after the injury (or a first needle-operation), in a week or thereabouts, the whole lens is much swollen altogether, and in cases where, by a subsequent needle-operation, it has been completely broken up and has become uniformly swollen and diffuent. In the youngest patients, it is most



probable that the natural process of absorption will suffice to effect the removal of the lens-matter without risk of inflammation. If it should be altogether very much swollen, even if there be no dangerous symptoms, it is well to hasten the cure by evacuating at least the major part of the soft cataract. Not unfrequently the wound in the cornea, through which the lens was wounded, will be the most convenient way of reaching the lens ; and often, when a soft swollen lens-mass is pressing outwards the lips of the wound, the thin weak recent cicatrix retaining it may be easily traversed with the end of the suction-curette, and so it may be altogether removed without any cutting instrument. The operation is a very admirable one, and, if practised carefully in the above-mentioned cases, it deserves more consideration than it has obtained. Diffluent lenses used to be evacuated by the curette ; a sufficiently large opening having been made with a broad needle, the curette was introduced into the anterior chamber, and a gush of the aqueous humour and lens-matter took place, and then, by various little movements to-and-fro, a little more of the lens-matter was made to flow along the groove of the instrument. Now, in such a case, by using the syringe, with the end like that of a curette, but made tubular, keeping the point of it in the posterior aqueous chamber, and the orifice being forwards, we can, without any movements endangering the iris, *suck out the whole of the diffluent lens-matter*. The corneal opening is made with a broad needle, which should be made to enter also the lens and lacerate the capsule, if necessary. It should be large enough easily to admit the suction-curette ; and the point of this, when once introduced, should be brought into *the centre of the pupillary area*, and then carried back until it is *in contact with the posterior lens-capsule*. When there, the point *should not be moved about*, or it may draw in the iris, or afterwards the cornea, with the lens-matter, or bruise the iris. The patient being recumbent, and the point of the instrument kept well back in the posterior aqueous chamber, in the hollow of the posterior capsule, all the diffluent lens-matter will fall towards the orifice and be drawn in succession into the syringe. If, in a case of a swollen accidental or surgical traumatic cataract, the Surgeon cannot be sure that the lens-substance is completely dissolved in the aqueous humour, after a lapse of time amply sufficient according to the age of the patient (the older the patient, the slower is the cataract in becoming dissolved in the aqueous humour), it will be better to defer the use of the syringe until some evidence of irritation, redness in the ciliary region, &c., shows itself. In no case would it be necessary to wait more than a week or ten days ; but, if the lens-matter be imperfectly dissolved, some fragments clog the small tube of the syringe, and then it is necessary to remove the instrument from the eye, and reverse the action so as to force out the fragment causing the obstruction in the tube of the syringe. This necessitates the introduction and reintroduction and various movements of the syringe, almost as much as used to be required with the old curette in the anterior chamber.

The suction-curette is invaluable, especially for the total removal of the whole lens at once, without any previous needle-operation on an earlier day, by a very small opening in the cornea, in diabetic and other quite exceptional cases of cataract ; and next in those in which the preliminary operation (or an accidental wounding of the lens) has, after a little while, made it possible and desirable thus to remove the lens, or a great part of it, in a large number of cases ; for, with the suction-curette, the corneal opening need be only very small, and the parts concerned little disturbed. The great amount of swelling of the cataractous lens-substance, and the evenness of its bluish-white tint, are, together with the history of the case and the age of the patient considered, the best indications that can be obtained of the practicability of a suction-ope-

tion ; but if, in any case, the operation should prove to be impracticable, it has no way precluded a subsequent traction-operation with a larger opening in the cornea. It is also, in different cases, sometimes useful in other operations for cataract, in cases where the old-fashioned open curette would have been used, so as to employ suction-power instead of traction, &c. Whenever a cataract has been removed by flap-extraction or smaller corneal section, and soft cortical matter and shreds of lens-capsule remain, less injury to the parts is probably done by use of the suction-curette than by the old curette or other traction instrument ; but the latter must be used in many cases when the cortical matter, &c., is not very soft, and the suction-curette becomes clogged. As to the shreds of lens-capsule and lens-matter involved, the grooved curette cannot possibly remove them, and considerable fragments of lens-matter cannot be removed with either the suction or the grooved curette so readily as with a scoop. The grooved curette acted best when, with the first gush of aqueous humour along its groove, the opportunity was taken to let pass along with the aqueous humour as much as possible of the diffuent lens. Now, with the suction-curette there is no voluntary gush along the tube of the instrument when it is introduced, only beside it, perhaps, and the space beside it is not large enough to let pass any but the smallest fragments that may come in the way ; so, not to lose the opportunity given by the natural force of expulsion and the greater quantity of fluid contents, we must begin to employ the suction-power as soon as possible after we have entered the suction-curette in the anterior chamber, or the aqueous humour without the lens-matter may be running to waste.

SECONDARY OPERATIONS FOR CATARACT.—Opaque matters on the capsule of the lens, remaining after removal of cataract by any one of the various fore-mentioned methods, very often necessitate a final operation ; without which, indeed, the promised good result of the operation—for there has been no iritis in these simple cases—is in abeyance. When it is plain that this little operation will be required, it should be done as soon as all redness, remaining after the primary and major operation, has disappeared from the eye ; for, if it be long deferred, the capsule becomes so tough that it cannot be torn through without much force, or the use of two needles, and even then, perhaps, a rent insufficiently large is made ; and, moreover, the force used, and the dragging made on the parts around, may light up an inflammation which will after all close the aperture made in the capsule. It is seldom indeed that, with a pupil widely dilated, one cannot see, after removal of the lens, some opaque patches and streaks left upon the posterior capsule *in situ* ; but these are very often only found in the margin, and there chiefly in most cases where they are generally distributed. Others consist of shrivelled-up remains of the anterior lens-capsule, and of traces of the cataract itself ; and yet, although these may be considerable, if they have been drawn away towards the circumference with the retracted capsule, as they are usually, all ways *behind the iris*, when not under the influence of atropine, they will require no needle-operation. If the central parts be clear, there would seem to be no obstruction to vision, and the patient should have good sight ; but, as in doubtful commencing cataract-cases, we have two methods of examination—the ophthalmoscopic mirror, and, if this fail to show us any opacity, or to explain otherwise why vision, with proper spectacles, is still imperfect, oblique illumination, by which, sometimes, such a puckering of the posterior capsule is detected as (without any opacity) to require an opening to be made in it with a needle. By the ordinary needle-operation for these secondary cases, when there is a central obstruction, the opacities are but thrust away and subsequently left to be drawn aside alto-

gether, and permanently, by the shrivelling of the lacerated capsule, leaving thus the central part free and unobstructed.

The eye is fixed open and steadied by use of the wire speculum and toothed forceps ; or, if one needle only will be wanted to be used, the operator may employ the fingers of his left hand instead of both (see Fig. 455); then he passes into the anterior chamber, through some marginal part of the cornea, wherever it may be most convenient, and not very obliquely through the coats, a cataract-needle, the point of which is then brought down towards the capsule, and so far as to reach some way across it to the side opposite to that at which it has been entered: the capsule is then penetrated: and, without passing the instrument any further into the eye, the point is carried back, and towards the side at which it has been introduced. The needle should traverse imperceptibly the capsule, but it may have become tough, and offer some resistance ; or, in an old neglected case, although it may be perforated, it is so very tough and elastic that it cannot be torn, without the help of another needle entered on the opposite side of the cornea. And we may not merely regard the opening that is to be made without considering the force used : the operation must be done without any dragging upon the ciliary processes and surrounding parts, or iritis or even ophthalmitis may be set up in the eye.

Sometimes after cataract-operation, a fragment of opaque lens-matter, enveloped in capsule, remains in the pupil : as it is a deformity, but chiefly because it obstructs vision, it must be displaced or removed. With a needle it may be detached at the parts at which it is least firmly attached in the circumference, and then it may be pushed aside, and perhaps it will be retracted behind the iris, and remain out of sight, and, as regards the patient, offer no obstruction to vision : it does no harm and may be left there, but, if it remain very loose, sometimes or always appearing in the pupil, and interfering with vision, or if in the former needle-operation it seem to be but slightly connected with the surrounding parts, then it may be removed with iris or cannula forceps, introduced by a sufficient opening made in the margin of the cornea with a knife or a broad needle. This may only be done if its attachments be weak ; if they be strong, perhaps they can be cut through first of all with iris or cannula scissors, and the forceps then used. With iris-forceps and iris-scissors we have much more power and certainty than with the cannula instruments ; but for their use we must, of course, have a larger corneal opening. Sometimes, and not unfrequently, an opaque band or two are found behind the pupil, after cataract-operation, in the level of the posterior capsule; if one of these be in the way of vision, it may, if recent and not thick, and if it cannot be broken through with a single needle, be twisted and broken by two needles introduced from opposite sides, or divided with scissors : then it will retract and remain out of sight. The twisting operation is somewhat dangerous, by reason of the dragging it may cause upon the ciliary processes, &c. Experience in this and in other eye-operations only will inform us how much force may be used ; but if the eye be otherwise useless, some operation must be done at all events, and I think in such cases probably it is best boldly to make a quarter section of the circumference of the cornea with a knife, then to introduce the points of a pair of iris-scissors, having one point blunt to be kept next the cornea, and the other sharp to be thrust within the pupil, behind the band, and so to divide it and leave it in two parts. The cannula instruments, forceps and scissors, are introduced by making for them, with a broad needle, a preliminary opening in the margin of the cornea, wherever it may be most convenient, not very obliquely, or in use they will bruise the cornea, and only just sufficiently large so as to retain as much as possible of the aqueous humour,



tinued bleeding from the deep-seated soft parts many hours after the operation. It arises from parts inaccessible from their being far back in the orbit, and so much the more so when the areolar tissue of the orbit and lids is distended with blood: these become so tense and prominent, and pressure is so difficult of application in the midst of so much infiltrated areolar tissue and fat, even if one knew exactly whence the bleeding came, that it is difficult to overcome it when it occurs. <sup>It probably comes from striking small vessels.</sup> It has never but once occurred to me since I have used the cold water as above described, and the sponge and tight bandage subsequently to this, after the operation. In a previous case, very early in my practice, where perhaps in doing the operation I had not merely divided the parts close to the globe of the eye, I was called to the patient in the night after I had operated: The lids formed two enormous red protrusions, and a little stream of blood flowed continuously from between them: I tried the actual cautery ineffectually, and succeeded at last by thrusting long pointed rolls of linen soaked in tincture of perchloride of iron, in different directions, into the spongy mass. I had another case subsequently <sup>in a case of the above kind</sup> controlled by the application of a tighter bandage.

The operation was not really the only remedy, it is in itself is, I had a patient many years ago, whose eyes were so bad, so that I had performed several operations, and certainly the best eyes had separate summations applied, but they were employed, and one that which had been applied, this is many years ago, and in doing the operation, I had a great deal of blood, and I shall have another case of the kind.

It can never be worth while to do the operation of ~~abscission~~ <sup>excision</sup> in any case otherwise favourable for the operation, unless the patient intend to wear a glass eye; if he do not, the globe had certainly better be excised at once: and in such case, an operation has sometimes been done to create a permanent artificial ptosis, by removal of a part of the levator palpebræ muscle near its insertion into the cartilage of the upper lid, by an incision through the skin, just below the upper edge of the orbit; the lid then falls, and the vacant space is always covered by it. If, instead of carefully preserving the conjunctiva, as in cases of excision of the eye in which an artificial eye is to be worn, it be all removed, the lids will be evenly and permanently closed, and this I have done in some such cases. *Ernest Z and K.*

As to the old operation for extirpation of the globe, in which a great part of all of the surrounding contents of the orbit were, with it, removed with a large knife, it is never necessary, and therefore it is never done by able Surgeons, except in cases in which a malignant or other growth has penetrated the coats of the eye from within, and extended more or less into the soft parts around. Then these parts must be widely cut away, when the globe is excised, with a pair of scissors, as may be most convenient. A.

ABSCISSION.—A few years ago this operation was much more in use than it now is. It is applicable to cases in which there is no essential pain, in which the disease, staphyloma corneæ generally, is confined to the front of the globe, so that by this operation, at least probably and mainly, all the parts diseased may be removed. <sup>The cause of corneal staphyloma above referred to, is, in some cases, the general vascularization of the cornea, not to be confused with the vascularization of the sclerotic, which is a term applied to any bulging of a part of the coats of the eyeball, either of the sclerotic or corneal, or of any tissues replacing these proper coats.</sup> Staphyloma corneæ generally begins at a part at which there is a scar, the cicatricial tissues being, if not thinner, at least less capable of resisting, intraocular pressure, <sup>which together with occasional irregularities, form ridges at the seat of cicatrizing, intraocular pressure,</sup> whether of the normal amount or in excess. The staphylomatous parts may have been merely weakened by old inflammation, without any breach of surface; or actual loss of substance may have been replaced by imperfect tissues that give way, if not at once, with very little provocation. A sclerotic staphyloma will involve the other coats within it, which also become expanded and thinned: A corneal staphyloma frequently carries with it the iris, which had become adherent to the posterior surface of the cornea, when the disease, the first cause of the staphyloma, brought them into contact, and thus it is expanded over the bulged cornea behind it. A corneal staphyloma generally has a central white patch, ill defined in the comparatively clear

or all of the surrounding contents of the orbit were, with it, removed with a large knife, it is never necessary, and therefore it is never done by able Surgeons, except in cases in which a malignant or other growth has penetrated the coats of the eye from within, and extended more or less into the soft parts around. Then these parts must be widely cut away, when the globe is excised, with a pair of scissors, as may be most convenient. A.

Staphyloma corneæ generally begins at a part at which there is a scar, the cicatricial tissues being, if not thinner, at least less capable of resisting, intraocular pressure, whether of the normal amount or in excess. The staphylomatous parts may have been merely weakened by old inflammation, without any breach of surface; or actual loss of substance may have been replaced by imperfect tissues that give way, if not at once, with very little provocation. A sclerotic staphyloma will involve the other coats within it, which also become expanded and thinned: A corneal staphyloma frequently carries with it the iris, which had become adherent to the posterior surface of the cornea, when the disease, the first cause of the staphyloma, brought them into contact, and thus it is expanded over the bulged cornea behind it. A corneal staphyloma generally has a central white patch, ill defined in the comparatively clear

We have nothing here to do with any staphyloma unless it is, in fact, a case of the cornea for, as respects the operations on the eye, nothing is ever done, directly or indirectly, for a staphyloma which does not involve the cornea. It is not to be excised, as one might think, but to be treated, and to be removed, in a case of a staphyloma, by a, worse still, admission of stump, and exposing its fellow eye in the future.

*a. bulous* - tissues around it, the leucoma marking the old disease in which it had begun, ~~A small partial~~ <sup>central or corneal</sup> ~~staphyloma~~ <sup>staphyloma</sup>, in a seeing eye, ~~may be~~, if sufficiently well defined, <sup>and the eye seen at half sight, may be</sup> simply removed with a knife, ~~leaving the remaining clear cornea~~ in the hope it will firmly cicatrise, and not again bulge, and afford still useful vision; but such a case is not often met with, nor is the hope then often fulfilled. If an eye with total but inconsiderable <sup>in length, called a staphyloma</sup> staphyloma corneae retain some vision, one can only do ~~abscission~~ <sup>excision</sup> or excision, if the patient decidedly wish it; then it may be done because ~~it will~~ <sup>we can</sup> only go on from bad to worse, and at a future time the operation will be inevitable. But in a case of extreme corneal staphyloma, the eye, very probably, still retains perception of light; and of this, unless it be all the patient sees, the other eye being lost, no account must be taken, and the operation must be recommended. ~~Pain alone does not contra-indicate the operation of abscission, but it must be apparently such as is due only to the disease of the anterior parts of the eye, to the irregular surface and prominence of the quasi-corneal tissue, sometimes even exposed for some time to the air, and drying, as the lids can hardly close over it.~~

*the eye may be the best person of the which there is the best which the cornea is the best person*

*by the remaining clear cornea, the eye is useful*

*A staphyloma of the eye will can have dim sight unless by surgical interference, and the tendency is always to increase, rather than only in depth, but also in width.*

~~The object of the operation is to remove an useless and painful or unsightly feature, and to gain, instead of it, a low stump as a good foundation for an artificial eye. If we are careful to remove the lens, which is liable to chalky and other degenerations, and the ciliary body, which is full of muscular tissue, nerves, and blood-vessels, together with the offending parts, we get rid of future sources of offence, and very much lessen the chances of irritation and inflammation in it, and of sympathetic irritation and inflammation in the other.~~

~~But there are many cases in which abscission or excision, one or the other, is called for; and in these cases, generally, excision is undoubtedly advisable. In the cases of great staphyloma corneae, the deeper parts are only comparatively sound, and, even if they were quite sound, after abscission, the stump made by the operation, though one is very careful to remove the ciliary body and lens, does not seem practically to be very unlike some of the accidentally wounded and shrunken globes that always must be excised whenever the cases occur. The cases of corneal staphyloma are generally those of young persons, to whom personal appearance is more important than to those more advanced in years. If it were not so, the excision operation would be more generally adopted in cases of disease of the front only of the eye. The stump of an eye left, if it can be made useful, is a much better foundation for an artificial eye to be worn upon, than is the cushion only of the soft parts left far back in the orbit by excision; and the ocular muscles have a definite insertion and action. The healing of an abscised globe is tedious, and perhaps painful; whereas there is no trouble or anxiety whatever about the healing after the excision of an eye. But few comparatively of our hospital patients will or can have the opportunity in future years of continuing to provide themselves with an artificial eye, every year or two, when a new one is required. And it is absurd to do an abscission in any case unless the patient intend to wear a glass eye; he had much better have the offending globe removed at once and altogether, if for that reason only. In private practice we can better depend on our patients not neglecting any symptoms against which they are warned; and, of course, the stump of an abscised globe can be excised at any time if it began to be painful or tender.~~

~~Operation. An incision, oval horizontally, through the sclerotic and other coats of the eye, is made to enclose the cornea, ciliary body, and lens, all of which are removed together. Sutures may or may not be used to draw the sides of~~

the gap together, from above and below, to retain better the vitreous body, to hasten the time of healing, and leave a better shaped stump and smaller scar. But the sutures sometimes give much pain and keep up inflammatory symptoms during the protracted healing. Supposing they are employed, three or four stout and semicircular curved needles, each with a silver-wire or black silk thread, are inserted in a row above the cornea, at about half an inch from the corneal margin. These are respectively carried at some distance behind the ciliary body and lens, and brought out below the cornea at about as far from the corneal margin as they were when introduced. Then a puncture is made with a pointed knife through the coats of the eye at about half an inch external to the margin of the cornea, and by it one blade of a blunt-pointed scissors is introduced, and so an oval piece of sclerotic, including the cornea, &c., is removed altogether, and just within the points at which, above and below, the needles traverse the sclerotic. Then the needles are drawn through, and the sutures are tied in knots each to each.

## THE OPHTHALMOSCOPE.

The advantages of the ophthalmoscope, in a surgical point of view, and as an aid in the treatment of eye-diseases generally, have been alluded to (p. 334, *et seq.*).

Fig. 462 represents the way in which I recommend the instrument to be used. The patient rests and steadies his head against a high upright-backed chair.

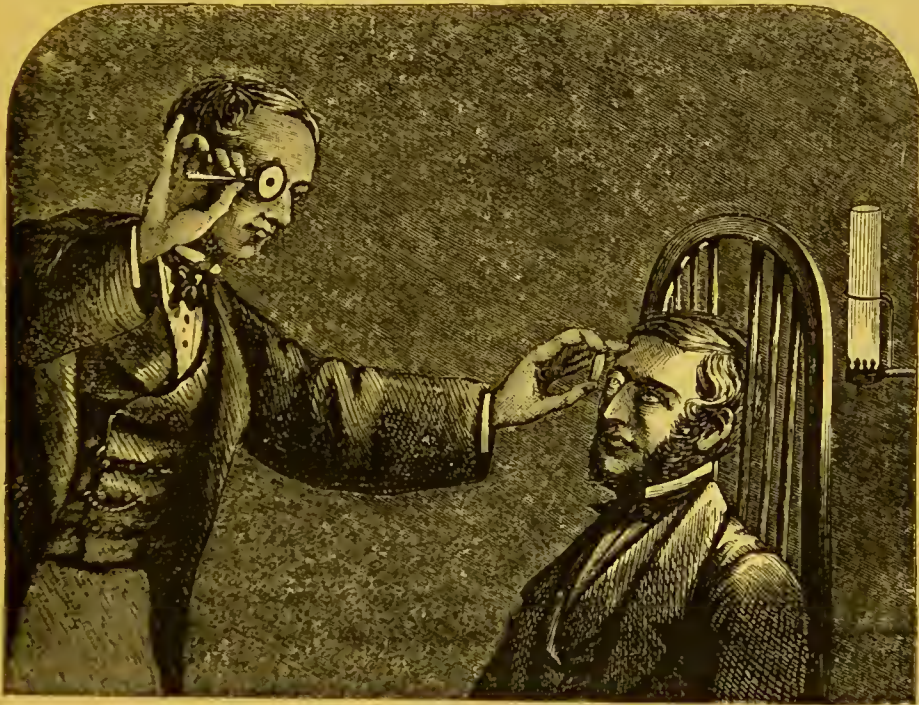


Fig. 462.—Use of the Ophthalmoscope.

(*Ophthalmic Hospital Reports*, vol. III. p. 64), and the observer, standing before him, can easily move his head, not only from side to side, as when he is seated in the way usually recommended, but he can as easily look from above or below; and this is more convenient, as he can more easily command his own movements than those of the patient's eyes. The best common ophthalmoscope

is Liebreich's. It has a small, polished, slightly concave metal mirror, reflecting enough light, but less, of course, than a silvered glass mirror, which moreover is usually made larger. The silver plate has a rather small central aperture, which is well defined as compared with that bored through the thickness of the glass plate or scraped in its silvering. The mirror is framed and backed in thin brass, painted black. A short black handle is appended, and to one side of the frame is a clip, to hold behind the hole in the instrument one of various small lenses, which are supplied with the ophthalmoscope. This clip is hinged, so that the lens contained by it can be turned aside when it is not required to be used. The mirror is held, as in the figure, to the right eye, to examine the right eye of the patient, and *vice versa*, with the handle horizontal, the little finger extended for the patient to look at, which if he does, then the observer (unless also the eye that is being examined is squinting) has in view the optic nerve-entrance in the fundus of the eye. And this is the best starting point, although the rest of the deeper parts of the eye remain to be examined. It is best to begin the use of the ophthalmoscope in the normal eye (the pupil dilated with atropine) of a young person of fair complexion. First, a reddish glare is seen, and this is lighter at the optic nerve-entrance. Then, in order to perceive the details of the fundus, the lens, held in the free hand of the observer, is brought before the eye that is examined at a distance of a few inches, and moved all ways in the line of the reflected light of the fundus, until the best image is obtained. This hand may be steadied against the forehead of the patient. This mode of ophthalmoscopic examination is the "indirect," (inverted image). It is that usually employed. Some practice with the ophthalmoscope is necessary before proceeding to examine the deep-seated morbid appearances within the eye. The preliminary use of atropine should be dispensed with as soon as possible in learning the use of the ophthalmoscope, and always afterwards, when the diagnosis without it is not made incomplete. Or at least it may be employed in weak solution, for one eye only (that of which the patient is independent—the worst eye—the least useful), and the patient forewarned of its temporary effects. Waiting for the pupil to become dilated expends time, and if atropine be indiscriminately used the increasing mischief, in some cases of nerve-blindness, &c., will be often ascribed to it. And for ophthalmoscopic diagnosis, it is only absolutely required in some obscure cases of commencing cataract or of vitreous and other opacities in the fundus oculi, &c.

With the ophthalmoscope, a lens or cataract dislocated by a blow into the vitreous chamber, and lying quietly at the bottom of that space, or gravitating perhaps to either side, may often be detected. Operation follows, of course, in this case the diagnosis afforded by the ophthalmoscope, which without it certainly would be impossible: an attempt at least must be made to remove the lens "conched" thus accidentally, in anticipation of the irritation and inflammation that it will set up. Dixon (*Ophthalmic Hospital Reports*, vol. I. pp. 280-5) reports a case in which he discovered by the use of the ophthalmoscope, in the ordinary way, a foreign body (a chip of metal) entangled in some remains of blood-clot hanging in the vitreous chamber. Thus aided, and having perfectly satisfied himself of the exact position of the foreign body, he made an opening through the sclerotic at a point opposite to that at which it was suspended, and succeeded in removing it with forceps. Also it is indispensable, previously, in desperate operations for evacuating the fluid of detached retina. Bader uses it, indeed, whilst he is actually operating. That is to say, he passes a long needle in through the sclerotic, &c., at a point opposite to the most prominent part of the detached retina, and, looking through the ophthal-



moscope, he makes the needle enter this prominence ; then he gives to an assistant the ophthalmoscope, to direct the light into the eye ; he then passes a second similar needle, also through the sclerotic, at a third of an inch from the first, and, not passing it further in than the first, he directs it to the same spot, so that it may also enter the detached retina ; and he makes them touch. Finally, by approximating the handles, without any other change of position of the two needles, he makes the rent in the retina. To be sure that this is done, he withdraws now the second needle, and examines the fundus again with the ophthalmoscope himself, to see if the subretinal fluid has entered the vitreous chamber, to see the rent if possible, or some evidence of the success of the operation. If there be none, he re-introduces the second needle, to repeat the operation.

THE END.



## REPORT ON OPHTHALMOLOGY.

By J. F. STREATFIELD, F.R.C.S.

---

*On the Colour of the Eyes of the Newly born.*—Dr. Alfred Wiltsbire had observed that it is blue, or, rather, “slaty,” and this, without exception, even in different races of men. (So it is also in the lower animals.) The “fœtal” blue begins to change usually in six or eight weeks after birth. If the eyes (irides) are destined to become “dark,” *i. e.* hazel-brown or black, a brownish hue overspreads the leaden blue, and in the course of a few months effaces it. Eyes that ultimately become brightly blue, whether the shade be light or dark, gradually clear up, as it were, like the sky after a thunder-storm. The author concludes by referring to the importance of the above observations in a medico-legal point of view.—*Lancet*, Feb. 11th, 1871, p. 188.

Dr. William Ogle, on this, points out that this remark was made specially of the human eye by Aristotle.—*Ibid.*, March 4th, 1871, p. 323.

Dr. J. H. Waters attributes their coloration to the influence of light. “We know their colour is derived from its action, for the eyes and hair of the newly born are without any decided colour for days after their birth.”

(Certainly not always: the last infant we have seen just after birth had an abundance of *bright-coloured*, *dark-brown* hair and *grey* eyes, and now, after six months, the hair and eyes are just the same.)—*Ibid.*, April 22nd, 1871, p. 534.

*Colour of the Eyes of the best Courier Pigeons.*—Mr. R. W. Alldridge, at a meeting of the West Kent Natural History Society, remarked on this subject that “pearl” eyes are preferred, but that one of the most celebrated birds now in Belgium has black or bull eyes. This bird has beaten all its competitors in travelling in foggy or very heavy weather, and has reached its home late of an evening, when the other birds have lodged for the night. He continues:—“The woodcock, snipe, and all night-flying birds possess black eyes. The wild duck has a piercing black eye, and not only flies at night, but sees well under water. The swallow, so active at the close of the

day, has similar coloured organs of vision. On the other hand, the cupulet, a pigeon scarcely known in England, has an eye infinitely whiter than pearl; it is the highest flying and the longest on the wing of all the pigeon tribe, and mostly chooses midday for its flight. He concludes that pearl- or white-eyed birds succeed the best in broad daylight and clear weather, and *vice versâ*. One bird flew 500 miles in one day. It is said that, in taking their course, at the outset, their vision enables the best birds, in particular, to recognise some familiar landmark in relation to their home.—*Standard*, April 10th, 1871.

*The Eye of the Mole*.—Dr. R. J. Lee shows that, though the foetal mole has an optic nerve, foramen, &c., both are completely atrophied or absent in the adult.—*Lancet*, July 9th, 1870, p. 55.

*Anterior Epithelium of the Cornea*.—The lowest layer of the anterior epithelium of the mammalian cornea consisting of cylindrical cells, contains in scanty distribution peculiar cells, whose chief distinction from those around them depends on the nature of their nuclei, which show remarkably granular oval corpuscles, whose intercellular layer mostly is with difficulty to be shown. In fine diagonal sections of the cornea through the epithelium, these corpuscles lie at an almost uniform little distance from the anterior elastic layer. Quite freshly examined, they appear more pale, by help of reagents as ellipsoid forms, which contain numerous heterogeneously grouped and arranged longish granules in a clear ground substance. Neither with the wandering cells of the corneal epithelium nor with the always double contoured nuclei of the neighbouring epithelial cells are these corpuscles to be confounded; the origin and signification of which is as yet entirely obscure.

From successive horizontal sections it is evident that the reproduction of the corneal epithelium does not proceed in the inferior, but essentially in the middle layers by division of nuclei. According to which one might have therefore to distinguish an inferior constant cylindrical-epithelium, and a superior constantly renovated division of the epithelium, consisting of flat cells.—*Centralblatt für die Medicinischen Wissenschaften*, May 28th, 1870, p. 383.

*Intimate Structure of the Vitreous in the Human Eye and in that of the Vertebrata generally*.—G. V. Ciaccio arrives at directly contrary results to those hitherto published, asserting that the minute structure of the vitreous in foetal life and in adults is absolutely the same; that the whole mass of it consists of a very transparent sticky homogeneous matter, and also of an extremely fine inextricable net interspersed in the same of extraordinarily numerous fine fibres felted together, which are intimately attached to the inner surface of the hyaloid. The fibrous network is especially evident when the vitreous has been treated with alcohol and chromic acid, but in the perfectly fresh condition traces of it may be discovered.

In the substance of the vitreous the author could never find the cells spoken of by preceding observers. On the other hand, in the fœtus as well as in adults, the whole inner surface of the hyaloid (as is easily shown by treating the vitreous prepared with the hyaloid uninjured, with carmine, fuchsine or osmic acid of half p. c.) is, as it were, thickly sown with roundish granulated cells (cellulæ subhyaloidæ), to which the author ascribes great importance both for the first formation of the vitreous and for its nutrition and regeneration.

In repeated chemical analyses of the vitreous the author always found water, NaCl, sometimes also  $\text{NH}_4\text{Cl}$ , a certain albuminous body, which, to Millon's reagent —  $\text{NO}_5$ , and  $\text{NH}_4\text{O}$ , behaved like the white of a hen's egg, from which, however, it is distinguished by the low power of coagulation with heat, by alcohol,  $\text{NO}_5$ , and tannic acid, and in small quantity (in the fœtus always more abundantly than in adults) a fat extractible by ether, but never the mucin announced by Virchow and others.—*Moleschott's Unters. z. Naturlehre*, X, 583—9.

*Dioptries*.—Dr. Dudgeon wishing to see distinctly in diving under water, has invented a biconcave *air* lens, or one made up of two sections of a hollow sphere of glass (two and a half inches diameter), the convexities towards each other, and their edges united by a water-tight metal rim. This is to replace the loss of the refractive power of the aqueous humour (“anterior lens”), and instead of its equivalent (+ 2) glass lens, which had to be adjusted to the eyes each time on going below the surface of the water. The *air* lens offers no obstruction to vision above water. It seemed to the author “the perfection of simplicity to compel the water which had taken away the vision to restore it by a new arrangement of itself . . . The media, which in the normal condition caused perfect vision, air and water, were again employed, but in an inverted manner.”

Dr. Dudgeon considers that the reason why authors differ so much as to the actual convexity of the anterior surface of the lens is that they have not observed that it is not the segment of a sphere, but that its external portion has a smaller radius of curvature than its centre (11.5 and 14 mm.). The latter alone concerns us.

Donders and others have overestimated the increase of curvature of the anterior surface of the lens in accommodation for near objects. The eye, after extraction of the (cataractous) lens, is compared to a spherical water lens, composed of the united aqueous and vitreous humours, with identical densities.—*Notes on the Dioptries of Vision* (pamphlet).

*Phenophthalmotropia*.—Under this designation Donders describes an apparatus, by means of which the movements of the eye, according to Listing's laws, may be represented. It consists essentially of a globe, which may be turned about within three rings around three axes standing perpendicularly on one another. By

turning within of the outermost ring every desired inclination can be imparted to the originally horizontal turning axis which was directed from the lateral to the median side, in which case it remains always in the plane perpendicular to the sight line. It is known that according to Listing's laws the eye turns around an axis, which stands perpendicular upon the first and second position of the sight line, which condition therefore is fulfilled in the apparatus. Also the inclination of the representations of horizontal and vertical lines and the solution of Helmholtz of the movements of the eye (raising and lowering, turning laterally of the sight line, rotation) may be demonstrated by the model, of which in the original a full description is set forth.—*Centralblatt für die Medicinischen Wissenschaften*, July 16th, 1870, p. 510.

*Test Types.*—Dr. B. Joy Jeffries, judging by his own vision, doubts if our tests are sufficiently nice—if the power of reading Snellen's No. XX, at 20 ft., is not considerably below the average. The doctor, *e. g.*, can read No. VIII of Snellen's types at the same distance, "when not feeling below par in general sensation of health." Of some recruits he has examined, he says:—"The same men who the day after a spree could not read my Snellen XL or L, would come back the day following and read XX fluently."—*Transactions of the American Ophthalmological Society*, 1869, p. 43.

*Accommodation.*—Brought about in the human eye by the ciliary muscle. Mr. Hnlke infers that the normal condition of the lens at rest is to be compressed and flattened, especially on its anterior surface, by the action of its suspensory ligament, and that the ciliary muscle, by drawing forward the choroid and processes, and slackening the ligament, allows the lens to assume a greater degree of anterior convexity.—*Lancet*, July 9th, 1870, p. 62.

*Traumatic Paralysis of Accommodation.*—Dr. G. C. Harlan reports three cases of this nature, two of them uncomplicated, a rare result of injuries. Dimness of vision and a widely dilated pupil were the leading symptoms *primâ facie*. Calabar bean was applied locally, and recovery was complete and speedy.—*Amer. Journ. Med. Science*, Jan., 1871, p. 139.

*Paralysis of the Ciliary Muscle from Diphtheria.*—Three cases of Mr. Hutchinson's are reported. The patients were children, and unable to read, and, unless there were also hypermetropia present, as in other cases of the kind, distant objects were well seen without a convex glass, such as is needed for reading when the muscle of accommodation is paralysed, without hypermetropia. "In a month or six weeks the sight is again perfect."—*Lancet*, Jan. 7th, 1871, p. 13.

*Epileptic Pupil.*—Dr. Clouston, as to the various states of the pupil in insanity, of which he considers a permanent contraction to be the most unfavorable prognostic, makes the following remark, "I

have observed a condition of the pupil in an epileptic which I have not seen described. The patient is a youth of seventeen, who has taken epileptic fits from birth. After each fit, just when the tonic spasm has ceased, if the eye is kept open and the pupil watched, there occurs what appears to me to be an epileptic convulsion of the iris. It dilates to its utmost extent, and then contracts rhythmically for over two minutes at least. The movements are, of course, slower than the jerking convulsions of the voluntary muscles, but appear to me to be of the same character. From what I have observed in other cases too, I am inclined to think that the hitherto unexplained movements of the iris during and after an epileptic fit, are in reality of the nature of the spasmodic movements of the voluntary muscles."—*Practitioner*, July, 1871, p. 21.

*Demonstration Ophthalmoscope.*—MM. Wecker and G. Roger presented to the Paris Académie des Sciences, a prismatic objective, with which two observers can explore together the interior of the eye.—*Archives Générales de Médecine*, June, 1870, p. 756.

*Ophthalmoscopic Demonstration.*—Dr. C. M. Gariel, in his recent publication, Paris, 1869, on the ophthalmoscope, has shown the possibility, theoretically, of getting objective images thrown on a screen, and thus, by a modification, to make them visible, at one and the same time, to a number of persons.—*Gazette Hebdomadaire*, Dec. 17th, 1869, p. 816.

*Ophthalmoscopic Signs of Death.*—M. Poncet, of Strasbonrg, has been investigating this point in man and animals. He has invented (and figured) a new ophthalmoscope for this purpose, which requires the eye to be observed in a dark chamber. In four to five hours, or less, the cornea is often too opaque for light to be transmitted, if the eyelids have not been closed. The cornea should be wetted with a drop of water to restore its transparency. Immediately after death the arteries generally disappear, and the veins are only shown by small, indistinct, irregular clots here and there. The choroidal plexuses are replaced by whitish or slightly rosy streaks in the pigment. The optic disc is yellowish white, in a fundus generally pale and doubtful in its aspect, without vascularisation but for the clots mentioned. The fact of death having occurred, or of the exact moment when it has occurred, may thus be determined in any doubtful cases.—*Archives Générales de Médecine*, April, 1870, pp. 408-24.

*Ophthalmoscopic Signs of Spinal Disease.*—Dr. T. C. Allbutt, in reviewing the facts, as they are known at the present time, adds to them his own observations. He says, in eight of thirty well-marked cases of spinal injury, secondary disturbance within the eye was found. These changes do not become established in the cases which run a short course, but they slowly supervene in the course of weeks or months in more chronic cases. In spinal diseases arising from injury, the higher the seat of the injury the sooner are these changes

in the eye. The (ophthalmoscopic) morbid appearances he arranges in two heads, the second including the traumatic cases: 1. Simple or primary atrophy of the optic nerve, sometimes accompanied, at first, by that slight hyperæmia and inactive proliferation which make up the state I have called chronic neuritis. This sort of change he has never found as a result of spinal injuries, but he has often met with it in chronic degeneration of the cord and in locomotor ataxy. 2. A somewhat characteristic hyperæmic change not seen in chronic degeneration, or in locomotor ataxy, but in cases of injury of the spine only. The retinal arteries do not dilate, but become indistinguishable, while the veins begin to swell and become somewhat dark and tortuous. The disc then becomes uniformly reddened, and its borders are low, the redness or pinkness commencing with increased firm vascularity at the inner border, which thence invades the white centre and the rest, so that the disc is obscured, or its situation known only by the convergence of the vessels. In many cases, rather than redness, he has observed a delicate pink—pink which sometimes passes into a daffodil colour. It ends in resolution rather than in atrophy. Sometimes the sight suffers a good deal in these cases, sometimes but little or scarcely at all. He has not seen true optic neuritis, with active proliferation, as a sequel of spinal disease. As to the processes connecting the changes in the spine and in the eye, the author, in the first place, objects to Prof. Wharton Jones's recent explanations of injury to the cord causing the sympathetic nerve or its origins to be involved, and so are, consequently, the blood-vessels, and nutritive changes are superinduced in the eye. He also objects that he has not observed, ophthalmoscopically, the dilatations of the arteries at and above the disc, to which Mr. Jones alludes. Can a palsied sympathetic be the ruin of the optic disc, when its effects are unseen in the pupil, unseen in the conjunctiva, unseen in the ear and cheek? Again, he says, it is a matter of verified observation, in numerous cases in which there have been most obvious signs of a palsied sympathetic in the ear, face, and outer eye, that in these very cases the back of the eye has been found unchanged. He is led towards the conjecture that hyperæmia of the back of the eye, following injury to the spine, is probably dependent upon a greater or less extension of meningeal irritation up to the base of the brain. Spinal meningitis does creep up to the encephalon, and if this ascending meningitis be the correct explanation, it accords with his observation that, in general, the higher the injury to the spine the sooner the affection of the eye. Atrophy of the discs is seen, not in injuries of the spine, but in slow degeneration of the cord, in cases, that is, where meningitis is usually absent or inactive, and it is seen most frequently by far in that degeneration of the cord called sclerosis of the posterior columns—of that part of the cord which tends to travel towards the encephalon, and not towards the periphery—up to the cerebellum.—*Lancet*, Jan. 15th, 1870, p. 76.

*The Ophthalmoscope in the Treatment of Epilepsy.*—Dr. Reuben Vance, of New York, distinguishes two forms of the disease, diagnosed



by the state of the circulation as seen in the retina;—the hyperæmic to be treated with bromide of potassium and depletion—and the anæmic with quinine, iron, and strychnia. In the latter class, the brain being anæmic during sleep, becomes a predisposing cause of the fits. In the congestive form they would be more likely to take place during the day.—*Lancet*, March 11th, 1871, p. 356.

*The Ophthalmoscope in Cerebral Disease.*—Dr. Hughlings Jackson would have the instrument always used in cases of doubtful nature, perhaps the so-called “bilious fever,” headache, vomiting, &c.; and if there is no renal disease, and the neuritis is double, it is strong evidence of some kind of coarse disease of the brain. *There may be neuritic changes, although the patient can read the smallest type.* The establishment of this and similar facts will enable physicians to foretell probable failure of vision in some cases.—*Medical Times and Gazette*, June 3rd, 1871, p. 627.

*Congestion Papilla.*—Mr. Swanzy reports a case of this kind in which he diagnosed, and there was found, after death, a tumour of the brain. The patient had constant headache, frequent vomiting, great drowsiness, and loss of memory. The pupils were dilated widely. One eye had slight perception only of light. He was ill four months. The tumefaction of the optic disc was very prominent, but did not extend far into the surrounding retina. The retinal veins were very much engorged and tortuous, disappearing where they turned round the edge of the tumid part. The extreme prominence of the papilla is depicted in a woodcut showing the eye, in two parts, cut open. The ophthalmoscopic appearances are given as a chromolithographic illustration. The author concludes by contrasting this state with that in neuritis descendens; the pathological changes in congestion papilla ceasing at the lamina cribrosa.—*Dublin Quarterly Journal*, February 1st, 1871, pp. 226—7.

*Meningitis and Pseudo-Meningitis.*—M. Bouchut characterises the latter as a morbid state of functional disturbance of the brain and meninges; as an acute febrile temporary state of disease, shown by fever, irregularity of pulse, vomitings, constipation, and pains in the head, brought on by reflex congestion of the membranes. It is particularly an infantile complaint. Not so only. The author goes on to say that by *cerebroscopy* one may discover in the eye unmistakable evidence of meningeal *congestion*. He refers to his former researches in this respect with the ophthalmoscope, from which he would deduce the following conclusions:

Congestion of the papilla indicates congestion of the meninges and of the brain.

Hyperæmia of the retinal veins, distended and filled by stasis or by clots, indicates repletion of the sinuses and thromboses of the meningeal veins.

Retinal hæmorrhages indicate venous compression.

Aneurisms of the retinal arteries indicate a similar lesion of the smaller cerebral arteries.

Papillary œdema indicates thromboses of the sinuses or of the cerebral veins.

Dotted choroidal atrophy indicates an incomplete general atrophy of the brain.

Atrophy of the optic nerve indicates sclerosis of the optic layers, and sometimes of the antero-lateral columns of the spinal marrow.

Cellular and granular exudations of the optic nerve indicate sclerosis of the nerve and its roots.

Tubercles of the retina and choroid indicate tuberculosis of the meninges or general tubercularisation, &c.

In fine, in most of the cases in which the functions of the cerebro-spinal system are disturbed, one may see something analogous in the eye.

In pseudo-meningitis, in face of more or less serious appearances of meningitis, embarrassing symptoms seeming to indicate the outset of this disease, one finds in the fundus oculi a congestion of the optic nerve without choroidal colouration or distension of the retinal veins, *i. e.*, a lesion signifying cerebral and meningeal congestion without acute inflammation of the meninges; in which case there would have been either peripapillary œdema or distension, varicosity, stasis, and thrombosis of the veins of the retina. The only difference between the true and false meningitis is a question of degree. In both, meningeal congestion is shown by papillary hyperæmia, but in true meningitis the ophthalmoscope shows a higher degree, the circulatory difficulty of the brain is indicated by papillary œdema, phlebotretinal stases and thromboses and retinal hæmorrhages or tubercles of the choroid, the clots of the sinuses, the ventricular effusions, and the tubercles of the meninges. The progress of the accidents only enables us to distinguish the true from the false meningitis. The pseudo-meningitis does not terminate in convulsions and paralysis. The author distinguishes five or six varieties of this disease.—*L'Union Médicale*, Nov. 11th, Dec. 4th—25th, 1869.

*Uræmic Amaurosis*.—Dr. Argyll Robertson distinguishes this from the comparatively common cases of albuminnric retinitis by saying, “Where the dimness of sight is due to nræmia, the amaurosis occurs suddenly, reaching its height in several hours—in some cases even in a few minutes. And the blindness is not unfrequently complete. Resolution occurs equally rapidly. In the other form the sight may also become pretty rapidly impaired at the commencement, but thereafter progresses more gradually, and after increasing for several days, remains stationary for a longer period. Very seldom does absolute blindness ensue. Resolution, too, when it does occur, proceeds very slowly.” The author points out that not unfrequently, “from the insidious progress of the disease,” the special ophthalmoscopic signs lead to detection of the serious general disorder.—*Edinburgh Medical Journal*, January, 1871, pp. 615—23.

Dr. Clifford Allbutt quotes an illustrative case. First of all the patient had had albuminnric retinitis, which had damaged his retina in certain districts only. Subsequently his sight became very

defective. This dimness of vision varied a good deal ; at one visit he could scarcely distinguish objects at all, or count fingers ; while at the next he wanted only clear vision of details. There were some symptoms of uræmia existing, such as drowsiness and occasional vomiting.—*Lancet*, June 3rd, 1871, p. 746.

*Glycosuric Amblyopia*.—Dr. Fitzgeraid related to the Dublin Pathological Society a case of dimness of vision in diabetes. There was no cataract, no hæmorrhages, only atrophy of the optic nerve and retina, and (the choroidal vessels and pigment islands were very well seen) the epithelial layer of the choroid implicated, “but this is only natural when we consider its very close relation with the external layers of the retina.” The opposite eye had been lost by an injury seven years previously (the lens dislocated).—*Dublin Quarterly Journal*, August 1st, 1870, p. 226.

*Bloodletting in some Eye Diseases*.—Mr. Hamilton, of Liverpool, protests against the almost entire disuse of local bloodletting. He employs leeches and cupping, and relates three cases, characterised by more or less evident hyperemia of the optic nerves and dilated pupils, corroborative of his views, of which also he gives a rationale.—*The Practitioner*, June, 1870, pp. 340-8.

*Squint Downwards*.—Surgeon Partridge, of Bombay, reports this case:—Captain E—, æt. 45, generally used only the right eye, and had acquired a habit of half closing the left at the time. Both being open, the left eye was turned directly downwards, or downwards and very slightly inwards. There was no paralysis. “Both eyes being uncovered, and he being told to look with the left eye only, the right eye was turned somewhat upwards.” The left inferior rectus was divided subconjunctivally and the squint perfectly cured. In the left eye ( $V = \frac{1}{4}$ ) the patient had mixed astigmatism. Glasses for the two eyes were ordered.—*Medical Times and Gazette*, March 4th, 1871, p. 243.

*Insufficiency of the Internal Recti*.—Dr. Swanzy says in muscular asthenopia (as distinguished from the accommodation) there are pains and sensations of tension, more especially, perhaps, in the brow. In accommodation asthenopia, “if work be proceeded with, the objects soon become indistinct ; in muscular asthenopia this is also the case ; but here, if the patient be reading, the indistinctness consists more in a shifting of the words and lines over each other than in a general cloudiness of them. In both forms a shorter or longer rest enables work to be proceeded with again ; but in the muscular form the benefit derived is less striking ; in it the rest must be of longer duration, and the periods of work shorter. Many persons suffering from muscular asthenopia learn to cover one eye with the hand during close work, by which means they succeed in evading the troublesome symptoms.” As a certain test, he recom-

mends the "equilibrium test," making use of the physiological fact that a prism stronger than  $1^\circ$  or  $2^\circ$ , held with its base upwards or downwards before one eye, produces unconquerable diplopia, such as, in other words, few can by their superior or inferior rectus overcome. Then a dot on a piece of paper will appear as two, the one not only above the other, but to one side; for no muscular effort can result in single vision, and so the eye passively deviates outwards. It is accurately measured and recorded, and the details more or less of the operative procedure (tenotomy of the external rectus) are by this to be accurately regulated, according to an empirical scale of Von Gräfe's. The gymnastic treatment is given up.—*Dublin Quarterly Journal*, Aug. 1st, 1870, pp. 35-49.

*Myopia in the Army.*—M. Giraud Teulon says, "Myopia is a cause of exemption in the French but not in the German army, in which it could be so much more often successfully pleaded as appertaining especially to the more studious nation." In the French army the number of exemptions on the ground of myopia does not exceed 4 or 5 per 1000 in the country districts, while in the town districts it is much larger. In the Paris Polytechnic School also, at one of the recent inspections for admission, myopia was found to be as high as 35 per cent. The wearing spectacles may well be set against the advantage of having soldiers who are well instructed, and able to find their way in an unknown country by means of the constellations." To obviate simulation of myopia in a recruit he would always adopt the ophthalmoscopic test. Medical examiners want instruction. Myopic soldiers should not be put to services calculated to aggravate the disease.—*Med. Times and Gaz.*, Aug. 27th, 1870, p. 246.

*Blepharitis.*—Mr. Carter very truly remarks that neglect on the part of the patient, and want of painstaking on the part of the surgeon, are the causes of its ill results. At the outset he uses a warm alkaline lotion—five grains of bicarbonate of soda to an ounce of water.—*St. George's Hospital Reports*, 1871, p. 351.

*Purulent Ophthalmia.*—Mr. Power considers it probable that this ophthalmia, *i. e.* an ophthalmia with a purulent discharge, although it goes on to a rapidly fatal result, may be merely a catarrhal ophthalmia in a weak or cachectic subject.—*Ibid.*, 1871, p. 322.

*Sympathetic Ophthalmia.*—Mr. Power considers that this never occurs unless the injured eye is amaurotic, *i. e.*, as he afterwards tells us, completely blind.—*Ibid.*, p. 325.

*Cataract: Early Operating.*—When both eyes are affected by cataract, and this is progressing equally and slowly, Mr. Carter would hasten the maturation of the cataract in one eye by opening the capsule with a needle—a practice much followed, we believe, of late by Mr. Bader, of Guy's. The author would even do this, under certain extraordinary circumstances, if the non-cataractous eye were blind.—*The Practitioner*, March, 1871, pp. 165-6.

He contrasts the advantages of this artificial maturation with the method of extraction of the immature cataract in its capsule. "In all cases in which trouble is to be anticipated from the adhesive character of the still transparent cortex, the surgeon has the additional resource of extracting the lenticular system in its entirety, the lens in its unbroken capsule. But a transparent cortex generally implies a condition of rather firm connection between the hyaloid and the posterior capsule, and there is then constant liability to loss of vitreous prior to the escape of the lens. When this happens, or when the lens resists moderate pressure, it becomes necessary to use traction instruments; and the operation has then been followed, in some instances, by inflammation and cell-proliferation in the vitreous itself, causing turbidity that only very slowly disappears. Moreover, the extraction in the unbroken capsule requires a very large iridectomy, likely to be productive of dazzling and imperfect vision; and it also requires a rather large external section, which increases the risk to the cornea. On the whole, therefore, the dangers of this method are probably greater than those of puncture as a preliminary to extraction, and its advantages in respect of saving time and of perfection of vision are only obtained when the course of events is altogether without accident or complication."—*St. George's Hospital Reports*, 1871, p. 345.

*Corelysis and Paracentesis for results of Iritis.*—Mr. Carter suggests that Streatfeild's spatula-hook should be made to *cut* in the notch, for which purpose the latter should be somewhat larger than he made it. Mr. Carter fears irido-dialysis, and he further suggests that the spatula-hook be made bent on the flat for its use on the *nasal* side of the eye. When, in iritis, the tension is increased, and only recently, Mr. Carter does paracentesis and evacuates the aqueous humour, "by opening the little incision by a fine probe, or by the beak of Weber's lachrymal knife. In most cases it will be desirable to introduce the probe two or three times a day for the first few days, and thus to establish a drain of aqueous humour, which will, in fact, be a sort of indirect depletion of the vessels of the eye.' (In a case of the intractable creeping ulcer of the cornea Mr. Carter incised it, and every day, for a week or ten days, reopened the incision along its whole length by the beak of a Weber's knife.)—*Ibid.*, 1871, pp. 356-7-9.

*Melanoma of the Cornea.*—Supplementarily to his experimental investigations on the formation of pigment in extravasation, Th. Langhans sought also to infer the pigmentation of melanotic tumours from the transformation of cells containing blood-corpuscles. In the case of melanoma of the cornea investigated by him, cells containing blood-corpuscles could not, of course, be any longer shown, as they had already many months been lying in spirit, but the pigment was collectively enclosed in cells, and the larger pigment-granules had yet, in part, clearly the form and size of the normal discoid or the altered globular blood-corpuscles; the colour of the

pigment was dark brown. By other observers cells containing blood-corpuscles have been found repeatedly near hæmorrhages in melanotic tumours. When, as in most melanotic tumours, no hæmorrhages have been found, penetration of red blood-corpuscles through the coats of the vessel may be assumed, and this action would be very much favoured by the capacious and thin-walled vessels of the melanoma.

The tumour in question, which was interesting in other particulars, was situated on the cornea, with a narrow base, fungus-like. Its surface was smooth, with little pigment; the deeper parts were extensively coloured of a dark brown by porous-like layers of distant vessels. It was placed upon a fibrous pannus-like mass, which grew from the conjunctiva, covering the anterior surface of the cornea, but without affecting its substance. On the other hand, a brown colouring extended from the tumour into the upper layers of the cornea, even beyond the tumour.

The coloured parts consisted of epithelial-like cells, which, without intercellular substance, were lying loosely together, and were partly pigmented, partly pigmentless. The cells were lying in round alveoli, the reticular spaces between which were occupied by vessels and closely compacted cells, which, for the most part, were more strongly pigmented than the cells of the alveoli themselves. In the parts non-pigmented the cells were much smaller, round, elongated, or spindle-shaped, closely compacted in a finely-granular or striped ground substance; the vessels were here also much finer.—*Centralblatt für die Medicinischen Wissenschaften*, May 14th, 1870, pp. 346-7.

*Calabar Bean in Suppuration of the Cornea.*—M. Galezowski says the contractile action exerted by the bean on the vessels of the cornea opposes their dilatation and congestion, and singularly aids the cicatrization of wounds. Belladonna, which produces opposite effects, should, he thinks, be discarded in these affections.—*Annuaire de Thérapeutique*, 1870.

*False Colouring and Indefinition of Objects by Santonin.*—Walter G. Smith, M.B., says, "On the 30th of August, a bright clear day, I took five grains of pure white santonin, half an hour after luncheon. While engaged in reading, some three hours after, I became gradually conscious of a yellowish tint on the paper, and fancied that there must be a yellow haze in the air. My own hands and the complexions of others appeared of a sallow, unhealthy colour, and the evening sky, which was really of a pale lavender tint, seemed to be of a decided light green. Vision was not perfectly distinct for some hours, and was accompanied by a certain vagueness of definition. This effect was followed each time after a dose of four or five grains of santonin, whether of the white or yellow modification."—*Dublin Quarterly Journal*, November 1st, 1870, p. 266.

*Microphthalmos.*—Mr. Wilson has exhibited to the Dublin Pathological Society an eye which he had extirpated. There had been a

metallic reflection from the fundus, but there was found to be no intraocular growth. The sclerotic was extremely thin, and the choroid almost pigmentless; hence the reflection, in the opinion of the surgeon. A small tumour (fibrous, and presenting several cyst-like cavities) was found attached to the posterior surface of the sclerotic and to the sheath of the optic nerve. The measurements approached those of most animals, the lateral diameter ( $8'''$ ) being greater than the antero-posterior ( $7\frac{1}{4}'''$ ). A coloboma iridis "enabled us to fix the period of gestation in which this arrest of development occurred."—*Ibid.*, Aug. 1st, 1870, p. 214.











